

# In Vivo Kinematics for Customized vs. Traditional TKA Designs: A Mobile Fluoroscopy Study

Presented by Ian M. Zeller, MS

ICJR Pan Pacific Orthopaedic Congress 2016 Presentation

Research grant provided by ConforMIS

## INTRODUCTION

Previous fluoroscopic studies were conducted using a stationary fluoroscopy unit that was not able to track the full movement of a patient. More recently, a mobile fluoroscopy unit was developed that can capture subjects performing unconstrained motions that more accurately replicate the everyday demands that patients place on their operated knees. The objective of this study was to determine the in vivo kinematics of subjects having either a Customized Individually Made (CIM) posterior cruciate retaining Total Knee Arthroplasty (TKA) or one of three traditional, Off-the-Shelf (OTS) posterior cruciate retaining TKAs.

## METHODS

108 subjects at two centers with either a CIM (44 patients) (iTotal, ConforMIS, Inc., Bedford, MA), OTS 1 (25 patients) (Vanguard, Biomet, Warsaw, IN), OTS 2 (25 patients) (Triathlon, Stryker, Kalamazoo, MI), or OTS 3 (14 patients) (NexGen, Zimmer, Warsaw, IN) TKA were assessed in this study. Fluoroscopic videos were captured of the patients while they performed both a deep knee bend to maximum knee flexion and a chair rise. Each video was digitized, corrected for distortion, and then analyzed to determine kinematics using a 2D-to-3D image registration technique.

## RESULTS

During a deep knee bend, on average, subjects with a CIM TKA experienced 3.82 mm of lateral posterior femoral rollback compared to 2.62 mm for subjects with an OTS 1 TKA, 0.97 mm for subjects with an OTS 2 ( $p < 0.05$ ), and 1.17 mm for subjects with an OTS 3 TKA ( $p < 0.05$ ) (Figure 1). Additionally, only 12.5% of subjects with a CIM TKA experienced an anterior slide of their lateral condyle during flexion—considered paradoxical rollback opposite to the normal knee—compared with 19% for OTS 1, 28% for OTS 2, and 36% for OTS 3. The average amount of axial rotation for the four groups was 4.44°, 4.59°, 5.80°, and 4.41°, respectively. Subjects with a CIM TKA achieved higher average weight-bearing flexion (105°) compared with OTS 1 TKA (102°), OTS 2 TKA (100°), and OTS 3 TKA (96°). During a chair rise, on average, subjects with a CIM TKA experienced 5.72 mm of roll forward for their lateral condyle, a motion pattern consistent with normal kinematics, while this amount was less for subjects with an OTS TKA (3.81 mm for OTS 1 TKA, 1.12 mm for OTS 2, and 0.19 mm ( $p < 0.05$ , for OTS 3). The average amount of axial rotation for the four groups was 7.58°, 6.95°, 8.92°, and 4.72°, respectively.

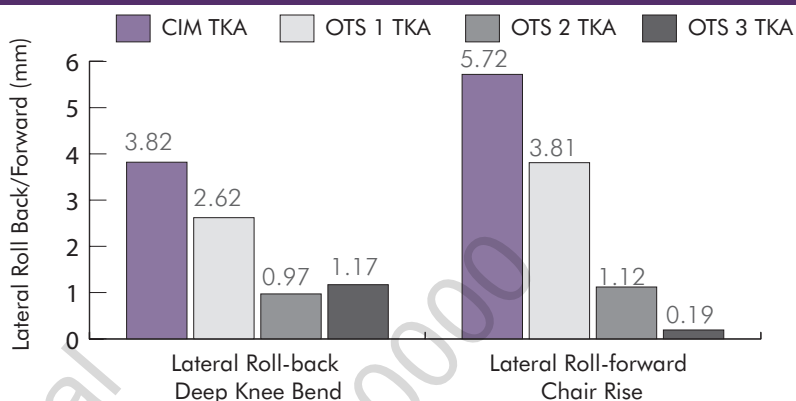


Figure 1: Comparison of average anterior/posterior translation for the CIM and OTS TKAs during Deep Knee Bend and Chair Rise.

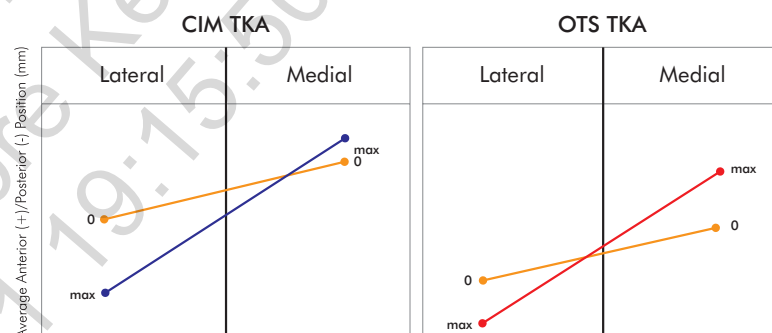


Figure 2: Representation of average kinematic patterns from full extension to maximum flexion during Deep Knee Bend. Normal knee pattern is large, lateral rollback with no medial anterior sliding.

## DISCUSSION

In this study, patients implanted with the CIM TKA experienced higher magnitudes of lateral condyle rollback during deep knee bend and roll forward during chair rise when compared to OTS TKA groups, patterns consistent with normal knee motion. Additionally, all OTS groups exhibited a higher possibility of an anterior slide motion opposite to the normal knee, when compared to the CIM TKA. Axial rotation between the four groups was similar. CIM TKA and OTS 1 TKA patients experienced rotation patterns due to higher rollback of their lateral condyle in combination with minimal translation of their medial condyle. OTS 2 and 3 TKA patients mainly experienced rotation due to less rollback of their lateral condyle in combination with a pronounced abnormal anterior slide of the medial condyle (Figure 2). Patients with the CIM TKAs also experienced the highest weightbearing flexion during deep knee bend. This study seems to suggest that matching implant shape to patient anatomy may improve kinematic function.