

Oper Orthop Traumatol
 DOI 10.1007/s00064-017-0484-x
 Received: 23 August 2016
 Revised: 13 December 2016
 Accepted: 13 December 2016
 © Springer Medizin Verlag Berlin 2017

Editor

W. Petersen, Berlin

Illustrator

R. Himmelhan, Mannheim



CrossMark

A. F. Steinert¹ · J. Beckmann² · B. M. Holzapfel^{1,3} · M. Rudert¹ · J. Arnholdt¹

¹ Department of Orthopaedic Surgery, Orthopädische Klinik König-Ludwig-Haus, Julius-Maximilians-University Würzburg, Würzburg, Germany

² Sportklinik Stuttgart, Stuttgart, Germany

³ Regenerative Medicine, Institute of Health and Biomedical Innovation, Queensland University of Technology, Kelvin Grove, Brisbane, Australia

Bicompartmental individualized knee replacement

Use of patient-specific implants and instruments (iDuo™)

Introduction

The treatment of bicompartmental knee osteoarthritis (OA) is challenging for both patients and surgeons. Recent studies showed that up to 28% of patients treated with total knee arthroplasty (TKA) suffer from a bicompartmental cartilage wear pattern only [1]. Furthermore, approximately 19% of all patients after total knee replacement still complain about persisting discomfort and are not satisfied with the surgical outcome [2]. Therefore, alternative treatment options are needed.

TKA in patients with bicompartmental disease represents an overtreatment especially in young patients. In these cases, not only the intact compartment is sacrificed, but also the anterior cruciate ligament that plays key roles in proprioception and kinematics of the knee joint [3]. For those patients, bicompartmental knee replacement is a good alternative, as it preserves all knee ligaments and resurfaces only the diseased compartments. Previous bicompartmental knee replacements were designed using a unicompartmental knee system combined with a patellofemoral replacement via two separate implants that were simultaneously implanted. At the same time, bicompartmental off-the-shelf monoblock implants found their way onto the market. These types of prostheses resulted in large parts in poor outcomes associated with up to 30% complications [4]. One of

the newest standardized bicompartmental knee replacements showed a good functional outcome for the majority of patients, but also an increased number of revisions were needed with 18% of implants that had to be converted to a total knee system in the first year due to pain, malalignment, or instability [5]. Reasons might be the technical complexity and the insufficient fitting of the prosthesis in relation to the individual anatomy of the patients. The weakness of the previous systems may be overcome by the patient-specific bicompartmental knee replacement system iDuo™ (ConforMIS Inc.). This patient-specific implant which is provided with individualized instruments enables an optimal bone-preserving implant fit, while knee ligaments can be balanced accordingly. Thus, an easy operation technique, and an optimal implant fitting can be achieved [6]. Preoperatively, a computed tomography (CT) scan of the affected lower extremity is performed, and based on this, individualized instruments and implants (ConforMIS Inc.; Burlington, MA, USA) are manufactured and provided together with a planning protocol (iView®) for the projected surgery. Individualized spacer blocks are provided to ensure an implantation which is adjusted to the tension of the ligaments, and guarantees a bone-sparing and soft-tissue-balanced surgical technique together with an optimized implant fit. The use of an additional

navigation or gap balancing system is not necessary.

In the following, we not only demonstrate the surgical technique, but also provide the first clinical results using the bicompartmental knee system iDuo G2™.

Advantages

- Patient-specific instruments (PSI)
- Patient-specific implants
- Patient-specific planning protocol (iView™)
- Optimal implant fitting
- Minimally invasive operation possible
- Ligament balancing included
- Bone and ligament preserving

Disadvantages

- Higher implant costs
- Need of CT imaging, increased cost and radiation exposure
- Increased waiting time for surgery
- Lack of long-term results

Indications

- Bicompartmental joint disease, combined medial or lateral with patellofemoral OA (osteoarthritis)

Contraindications

- Tricompartmental OA
- Ligament instability

A. F. Steinert · J. Beckmann · B. M. Holzapfel · M. Rudert · J. Arnholtz

Bicompartmental individualized knee replacement. Use of patient-specific implants and instruments (iDuo™)**Abstract**

Objective. Bicompartmental knee replacement in patients with combined osteoarthritis (OA) of the medial or lateral and patellofemoral compartment. Patient-specific instruments and implants (ConforMIS iDuo™) with a planning protocol for optimal implant fit.

Indications. Bicompartmental OA of the knee (Kellgren & Lawrence stage IV) affecting both the medial or lateral and patellofemoral compartment after unsuccessful conservative or joint-preserving surgery.

Contraindications. Tricompartmental OA, knee ligament instabilities, knee deformities >15° (varus, valgus, extension deficit). Relative contraindication: body mass index >40; prior unicompartmental knee replacement or osteotomies.

Surgical technique. Midline or parapatellar medial skin incision, medial arthrotomy; identify mechanical contact zone of the intact femoral condyle (linea terminalis); remove

remaining cartilage and all osteophytes that may interfere with the correct placement of the individually designed instruments. Balance knee in extension with patient-specific balancing chips. Resection of proximal tibia with an individual cutting block; confirm axial alignment using an extramedullary alignment guide, balance flexion gap using spacer blocks in 90° flexion. Final femur preparation with resection of the anterior trochlea. After balancing and identification of insert heights, final tibial preparation is performed. Implant is cemented in 45° of knee flexion. Remove excess cement and final irrigation, followed by closure.

Postoperative management. Sterile wound dressing; compressive bandage. No limitation of active/passive range of motion (ROM). Partial weight bearing the first 2 weeks, then transition to full weight bearing. Follow-up directly after surgery, at 12 and 52 weeks, then every 1–2 years.

Results. In all, 44 patients with bicompartmental OA of the medial and patellofemoral compartment were treated. Mean age 59 years. Minimum follow-up 12 months. Implant converted to TKA due to tibial loosening (1 patient); patella resurfacing (3 patients). No further revisions or complications. Radiographic analyses demonstrated ideal fit of the implant with less than 2 mm subsidence or overhang. KSS pain scores improved from preoperatively 5.7 to 1.7 postoperatively with level walking, and from 7.3 preoperatively to 2.8 postoperatively with climbing stairs or inclines. The WOMAC score improved from preoperatively 43 to 79 postoperatively.

Keywords

Patellofemoral knee osteoarthritis · Bicompartmental knee arthroplasty · Patient-specific implants · Knee joint · Patient-specific instruments

Bikompartmenteller individualisierter Kniegelenkersatz. Einsatz patientenspezifischer Implantate und Instrumente (iDuo™)**Zusammenfassung**

Operationsprinzip und -ziel. Bikompartmenteller Kniegelenkersatz bei kombiniertem arthrotischem Gelenkverschleiß des medialen oder lateralen und patellofemorale Kompartiments. Patientenspezifische Implantate und Instrumente (ConforMIS iDuo™) mit Planungsprotokoll für optimale Passform.

Indikationen. Bikompartmentelle Gonarthrose (Kellgren & Lawrence Stadium IV) am medialen oder lateralen sowie am patellofemorale Kompartiment nach erfolgloser konservativer und/oder operativer gelenkerhaltender Therapie.

Kontraindikationen. Pangonarthrosen, Bandapparatinstabilität, Kniegelenkdeformität >15° (Varus, Valgus, Streckdefizit). Relative Kontraindikation: BMI >40, vorheriger unikompartimenteller Gelenkersatz oder Umstellungsosteotomie.

Operationstechnik. Mittige oder parapatellare mediale Hautinzision, mediale Arthrotomie. Identifikation der Belastungszone des medialen Kompartiments (Linea terminalis). Entfernen aller Osteophyten die möglicherweise die Auflage der individuellen

Operationsinstrumente behindern könnten. Balancieren der Streckung mit patientenspezifischen Platzhaltern. Resektion der proximalen Tibia mit patientenspezifischen Schnittblöcken; Achsausrichtung mittels extramedullärem Stab und Balancierung der Beugelücke mit Abstandhaltern in 90°-Flexion. Finale Femurpräparation mit Resektion der anterioren Trochlea und endgültige Balancierung mit individuellen Probekomponenten. Einzementieren der Komponenten in 45°-Flexion, Entfernen der Zementreste, Spülung; Wundverschluss.

Weiterbehandlung. Steriler Wundverband, elastokompressive Wickelung. Keine Bewegungslimitierung. Schmerzadaptierte Teilbelastung für 2 Wochen postoperativ, ansl. Übergang zur Vollbelastung. Verlaufskontrollen direkt postoperativ, nach 12 und 52 Wochen, dann alle 1–2 Jahre.

Ergebnisse. Behandelt wurden 44 Patienten mit kombinierter medialer und patellofemorale Gonarthrose (Durchschnittsalter

59 Jahre). Nachuntersuchungszeit mindestens 12 Monate. Ein Wechsel auf totalen Kniegelenkersatz wegen aseptischer Lockerung, drei Reoperationen zur Implantation Retropatellarsersatz; sonst keine Revisionen, Reoperationen oder Komplikationen. Röntgenbefund zeigte durchwegs eine exzellente Implantatpassform postoperativ mit weniger als 2 mm Über- oder Unterstand der Implantate. Auch die klinischen Messwerte zeigten eine Verbesserung des KSS-Pain-Scores von präoperativ 5.7 auf 1.7 postoperativ auf ebenem Untergrund, sowie von 7,3 präoperativ auf 2,8 postoperativ auf Stufen oder ansteigendem Untergrund. Der WOMAC-Score verbesserte sich von präoperativ 43 auf 79 postoperativ.

Schlüsselwörter

Patellofemorale Gonarthrose · Bikompartmentelle Kniegelenksendoprothetik · Patientenspezifische Implantate · Kniegelenk · Patientenspezifische Instrumente

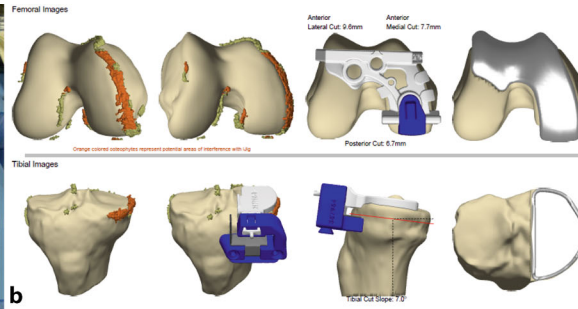
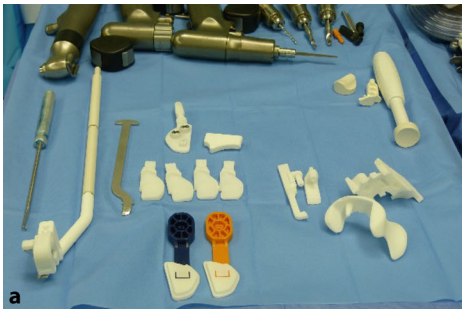


Fig. 1 ◀ Patient-specific instruments (a), the iView® planning protocol (b). Courtesy of ConforMIS

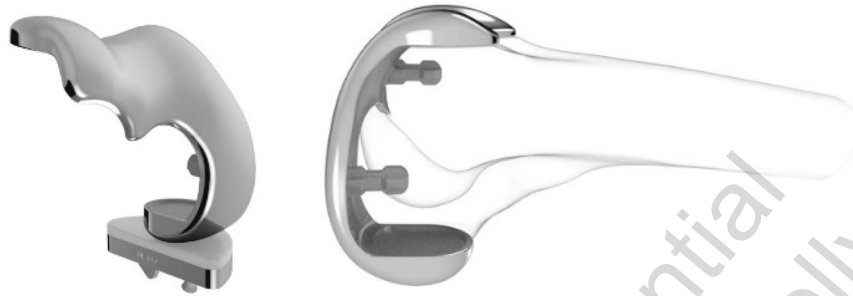


Fig. 2 ▲ Bicompartamental patient-specific implants. Courtesy of ConforMIS

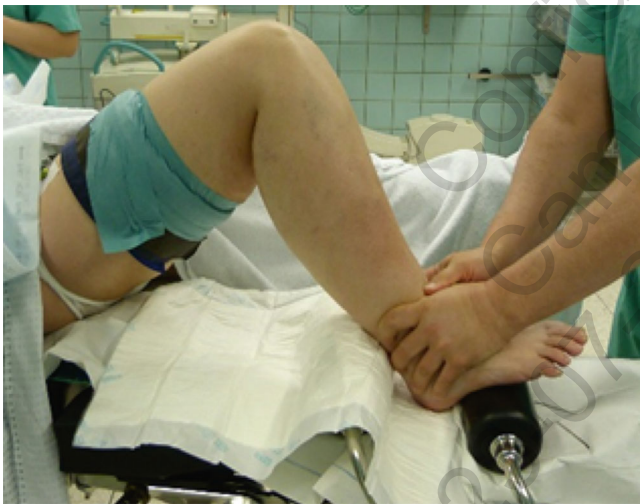

Fig. 3 ◀ Positioning of the leg

- CT imaging of the affected lower extremity
- Manufacturing of the patient-specific instruments and implants
- Depilation or shaving of the knee prior to surgery

Instruments and implants

- Implantation kit including patient-specific instruments (■ Fig. 1a), the iView® planning protocol (■ Fig. 1b) and patient-specific implants (■ Fig. 2)
- Commonly used instruments for knee surgery
- High-pressure irrigation (jet lavage)

Anesthesia and positioning

- General anesthesia or spinal anesthesia
- Positioning in supine position without pressure points
- Tourniquet is applied if desired on the thigh approximately 20 cm above the upper rim of the patella
- Positioning of the leg with knee roll or/and leg holder (■ Fig. 3)

- More than 15° knee deformity (flexion, valgus, and varus)
- Relative: prior osteotomies or implantation of knee prostheses
- Relative: obesity with BMI >40
- Postoperative partial weight-bearing and use of crutches
- Approximately 3 month rehabilitation period
- Repeated surgery in case of development of arthritis in the nonreplaced compartment

Patient information

- General operational risks
- Persistence of complaints
- Intraoperatively, conversion to a conventional implant may be necessary
- Implant loosening
- Intraoperative x-ray imaging
- Hospitalization time 3–7 days

Preoperative workup

- X-ray imaging of the knee including long-standing radiographs, anteroposterior and lateral views and axial patella view

Surgical technique

(**Fig.** 4, 5, 6, 7, 8, 9, 10).

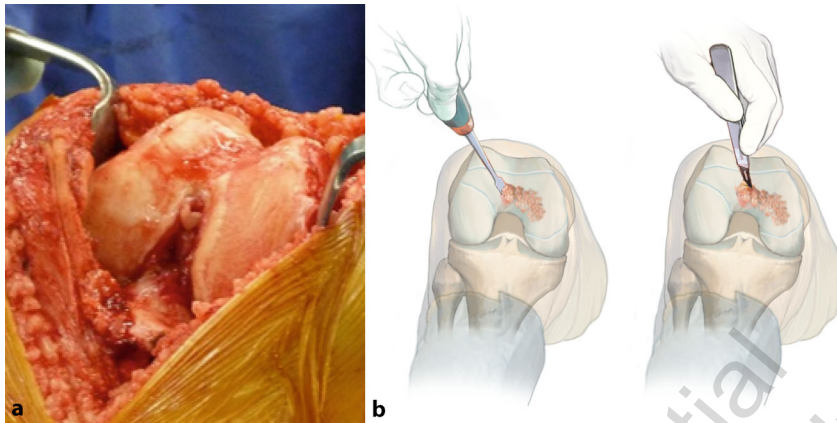


Fig. 4 ▲ Positioning in supine position without pressure points. Sterile wipe off and dressing with drapes. Skin incision starting from the medial patella to the medial tibial tubercle. Medial arthrotomy with sparing of the Hoffa fat pad, and confirmation of the pattern of anteromedial cartilage wear in order to reassure indication for iDuo™ surgery (a). Removal of the remaining cartilage in the anteromedial compartment through curette, chisel or scalpel (b)

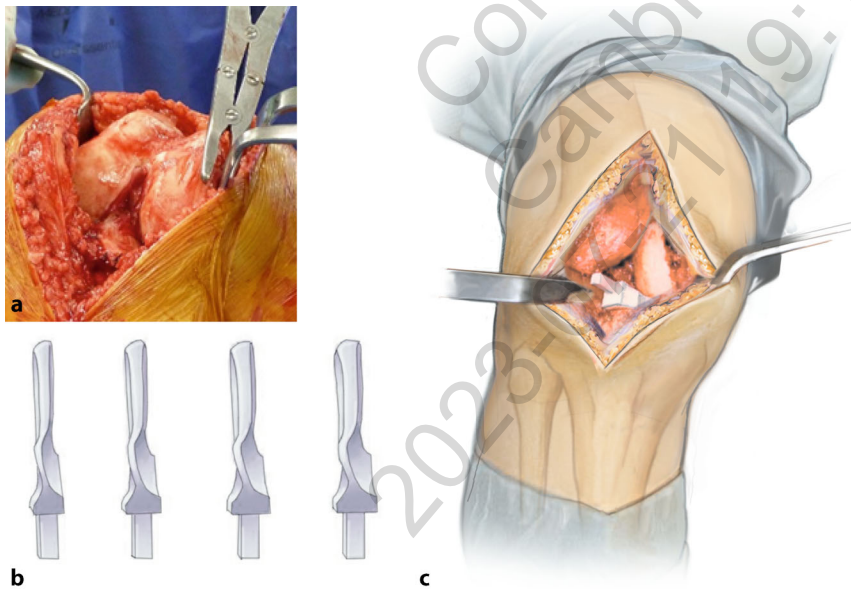


Fig. 5 ▲ Removal of osteophytes (Fig. 5) according to the iView™ planning protocol (**Fig. 1**; interfering osteophytes are labelled in red in the iView® plan). These two steps are crucial to correctly place the iJigs because the templates are referenced to the surface of the bone. Afterwards, the knee joint is balanced in extension using the patient-specific spacer blocks with incremental heights (A–D) (b). These spacers increase in height in 1 mm steps, with a patient-individual starting height as determined by the measurement of the extension gap in the preoperative CT scan. The optimal spacer block is confirmed by checking the stability of the ligaments in extension (c)

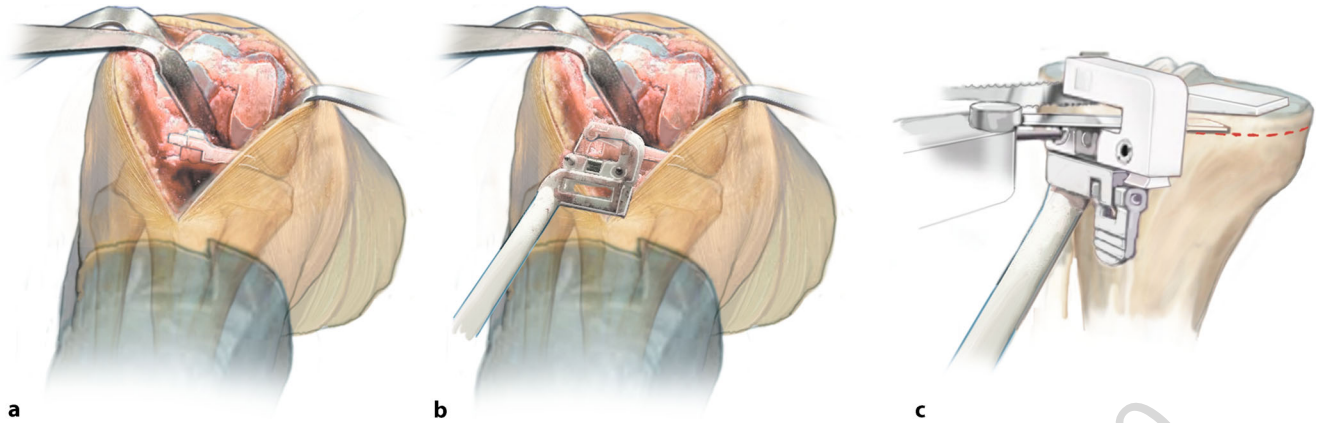


Fig. 6 ▲ The instrument for the tibial resection (tibial iJig™) is fixed on the balancing spacer block and its position is controlled using an extramedullary alignment rod (a and b). Drilling and pinning of the instruments for the resection of the medial proximal tibia. First, the vertical saw cut is performed with the jigsaw under protection of the anterior cruciate ligament (c). Afterwards the horizontal saw cuts are made under protection of the eminentia intercondylaris with a sawblade (c)

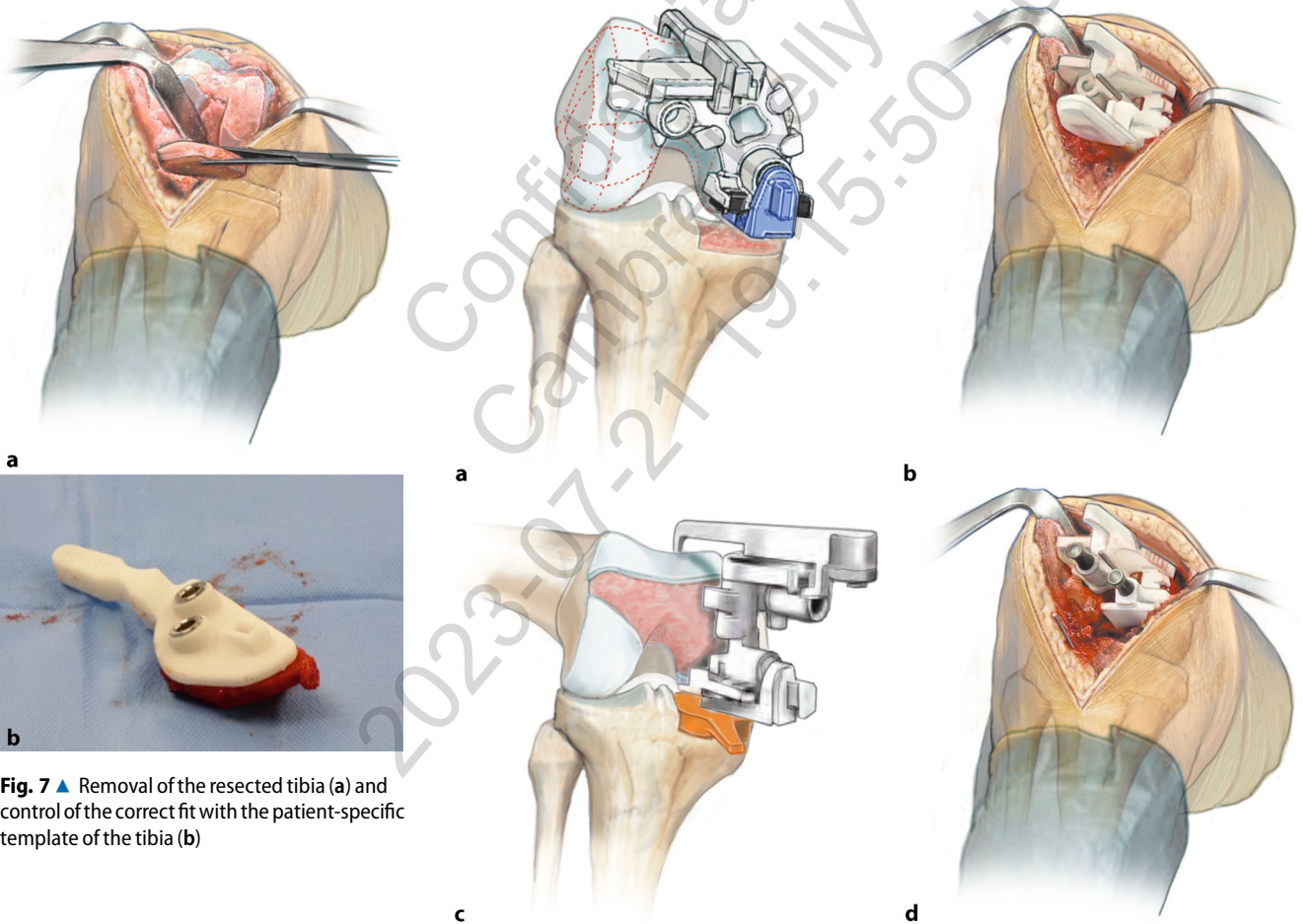


Fig. 7 ▲ Removal of the resected tibia (a) and control of the correct fit with the patient-specific template of the tibia (b)

Fig. 8 ▲ In 90° of knee flexion the flexion gap is balanced with different spacer blocks (orange 8 mm, blue 10 mm). The matching instrument is used for femoral resection (femoral iJig™) (a–d) together with the L-guide which matches the resection of the posterior condyle. As soon as the perfect matching position is reached, the iJig™ is drilled and fixed (d). Afterwards the posterior condyle is resected under protection with a Hohmann retractor. Then the thickness of the resected posterior condyle is controlled using a measuring gauge with addition of the thickness of the sawblade, and correlated to the iView™ planning protocol (■ Fig. 1b). If this measurement correlates with the preoperative planning, the resection of the ventral condyle with the trochlea is performed

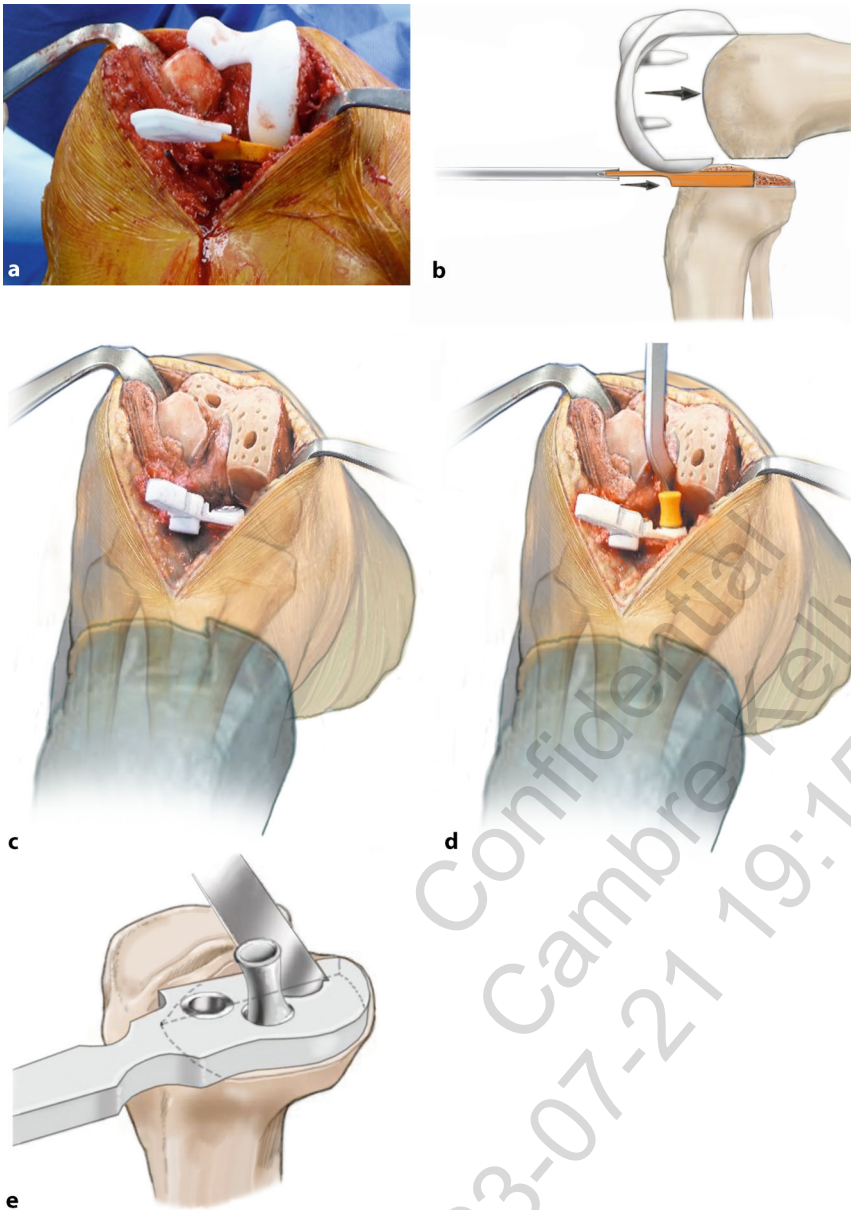


Fig. 9 ▲ The fitting of the femoral implant is controlled with a patient-specific test implant in combination with the optimal balancing spacer block (a and b). Afterwards the plateau of the tibia is finally prepared with an individual template that enables bone pits for the tibial component to be securely cemented. Therefore, the medial pod is drilled and pinned. Subsequently the lateral drilling is done, and another pod is created with a keel punch (c–e)

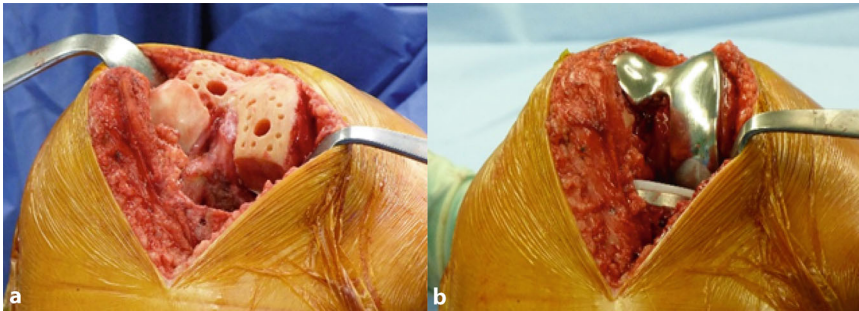


Fig. 10 ▲ Then drilling is performed in the sclerotic area to optimize cement penetration, and the situs is cleaned of debris with high pressure flushing (jet lavage). A dried bone area that is ready for cementing and implantation can be seen in (a). In the next step the original patient-specific implants are inserted and cemented with low viscosity bone cement (b). The sample inlay or the selected original inlay is then inserted. Cementing of the posterior elements should be performed carefully because the removal of the cement is difficult as soon as the original fixed bearing inlay is inserted. The insert height of 6 or 8 mm can be chosen. A tourniquet can be used if needed. Curing of bone cement is done optimally in 45° flexion. After curing, remains of the cement are removed, and the joint is irrigated. Opening of the tourniquet if used. Careful hemostasis. If not already done, the knee kinematics are finally tested and confirmed, and the original inlay is inserted. At the end of surgery, fluoroscopic imaging is recommended in two planes to prove the correct final positioning of the implants. A drain is usually inserted laterally at the proximal end of the wound. Wound closure in layers

Postoperative management

- Application of sterile wound dressing and elastocompressive bandage
- Removal of the intraarticular drain after 24–48 h, depending of the promotion amount
- Removal of the suture material around the 10th–12th day postoperatively
- Thrombosis prophylaxis until full load bearing is achieved
- Clinical and radiographic controls are routinely conducted directly postoperatively (■ Fig. 11), at 12 and 52 weeks postoperatively, and every 1–2 years afterwards
- Treatment regimen for the physiotherapist
 - Functional rehabilitation with pain adapted partial weight bearing for the weeks 1 and 2 postoperatively using crutches. No limitation of the active and passive range of motion
 - After removal of the drains, active and passive motion exercises are started. After 2 weeks postoperatively, swift transition to full weight bearing
 - Muscle building workout under supervision of a physiotherapist, ergometer workout

Risks and complications

- General surgical risks
- Fracture of the proximal tibia due to an inappropriately deep sagittal saw cut
- Malorientation of the tibial saw cut (slope and horizontal plane)
- Overstuffing of the compartment due to overcorrection (insert too thick)
- Instability due to undercorrection
- Intraoperative change of the surgical plan:
 - Total knee replacement in case of tricompartmental arthritis or insufficiency of the anterior cruciate ligament
 - Ligament reconstruction in case of insufficiency
 - Meniscus surgery and/or cartilage surgery in case of pathologies that affect the compartment that was not planned to be replaced
- Insufficient removal of osteophytes or ligament balancing

Results

Between 2014 and 2015, we implanted 44 patient-specific bicompartamental knee prostheses (ConforMIS iDuo™) in 44 patients (25 women, 19 men) using a medial arthrotomy. The average age of the patients was 59 (45–76) years at

the time of surgery. The procedure was performed in 2 centers by three experienced surgeons. There were no bilateral procedures. Preoperatively, the patient-specific instruments and implants were manufactured based on a computed tomography (CT) scan of the affected lower limb. In all cases the medial and retropatellar compartment were affected. In all, 44 patients (25 women, 19 men) were followed up clinically and radiographically for at least 12 months. In all cases radiographic analyses showed an ideal fit of the implants with less than 2 mm subsidence or overhang of the tibial and femoral implants and a central patella position (■ Fig. 11).

The mean Western Ontario and McMaster University Osteoarthritis Index (WOMAC score) increased from 43 (standard deviation [SD] ± 15) preoperatively to 79 (SD ± 16) one year postoperatively. The question “Does your knee feel normal” was answered preoperatively with “never” in 55%, “sometimes” in 43%, and “always” in 3%, while 12 month postoperatively this changed to “never” in 7%, “sometimes” in 37%, and “always” in 56% of the patients. The pain level was decreased as the VAS changed from preoperatively 5.7 to 1.7 postoperatively with level walking, and from 7.3 preoperatively to 2.8 postoperatively with stairs or inclines. The range of motion (ROM) improved from 122° preoperatively to 129° (range 115–140°) at one year postoperatively. One patient had to be converted to TKA due to tibial loosening, and in three patients a patella resurfacing procedure was necessary. All these three patients continued to be part of the study. No other complications occurred (e.g., infection, deep venous thrombosis). No patient included in this study required any blood transfusions or blood products.

The implantation of the patient-specific bicompartamental knee prosthesis iDuo™ G2 (ConforMIS Inc.) leads to good clinical and radiological results in patients with isolated bicompartamental arthritis. The patient-specific instruments and implants enable the surgeon to achieve optimal positioning and fitting of the prosthesis. The clinical and radiographic results are promising so

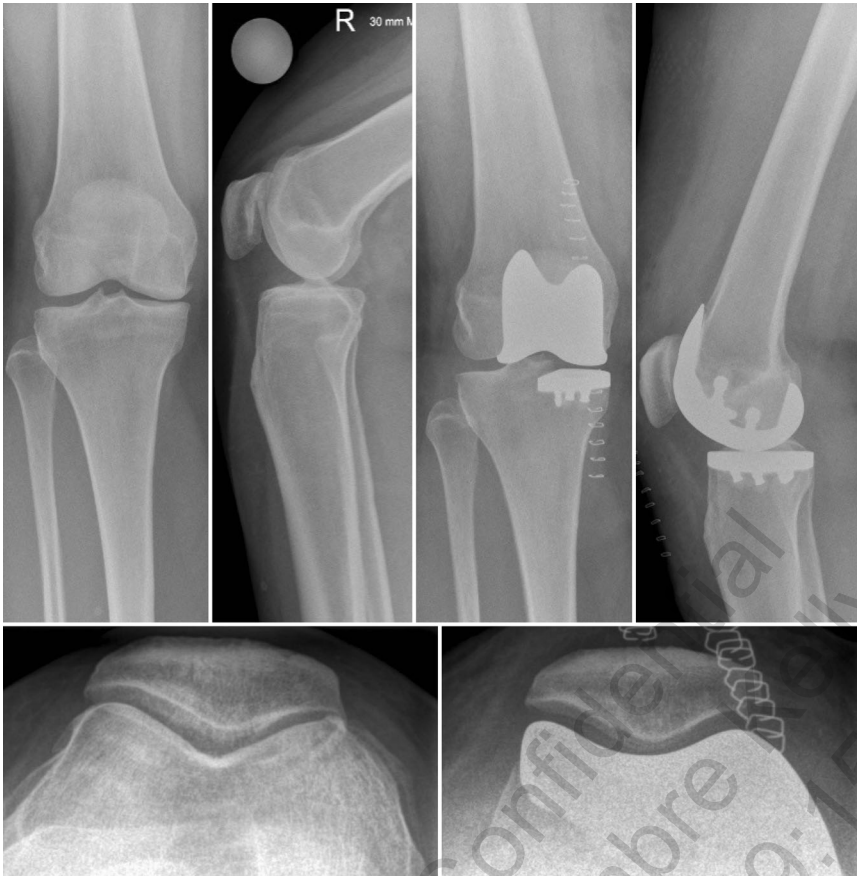

Fig. 11 ▲ Pre- and postoperative radiographic imaging of the knee joint in two planes with patella skyline view for a patient treated with a patient-specific bicompartamental implant ConforMIS iDuo G2™

far, but further long-term studies are necessary to prove the qualities of this new system.

Corresponding address

Dr. J. Arnholdt

Department of Orthopaedic Surgery,
Orthopädische Klinik König-Ludwig-Haus,
Julius-Maximilians-University Würzburg
Brettreichstraße 11, 97074 Würzburg, Germany
j-arnholdt.klh@uni-wuerzburg.de

Compliance with ethical guidelines

Conflict of interest. A. Steinert and J. Beckmann received support for consulting activities from ConforMIS Inc. M. Rudert states that he received institutional support from ConforMIS Inc. for training activities. B.M. Holzappel and J. Arnholdt state that they have no competing interests.

All procedures performed in studies involving human participants were in accordance with the ethical stan-

dards of the institutional and/or national research committee and with the 1964 Helsinki declaration and its later amendments or comparable ethical standards. Informed consent was obtained from all individual participants included in the study.

References

1. Heekin RD, Fokin AA (2014) Incidence of bicompartamental osteoarthritis in patients undergoing total and unicompartmental knee arthroplasty: is the time ripe for a less radical treatment? *J Knee Surg* 27:77–81
2. Bourne RB, Chesworth BM, Davis AM, Mahomed NN, Charron KD (2010) Patient satisfaction after total knee arthroplasty: who is satisfied and who is not? *Clin Orthop Relat Res* 468:57–63
3. Isaac SM, Barker KL, Danial IN, Beard DJ, Dodd CA, Murray DW (2007) Does arthroplasty type influence knee joint proprioception? A longitudinal prospective study comparing total and unicompartmental arthroplasty. *Knee* 14:212–217
4. Tria AJ Jr. (2013) Bicompartamental knee arthroplasty: the clinical outcomes. *Orthop Clin North Am* 44:281–286
5. Muller M, Matziolis G, Falk R, Hommel H (2012) The bicompartamental knee joint prosthesis Journey Deuce: failure analysis and optimization strategies. *Orthopade* 41:894–904

6. Beckmann J, Steinert A, Zilkens C, Zeh A, Schnurr C, Schmitt-Sody M et al (2016) Partial replacement of the knee joint with patient-specific instruments and implants (ConforMIS iUni, iDuo). *Orthopade* 45:322–330