

# matrix<sup>®</sup>



## Dr. Viorel Radukan

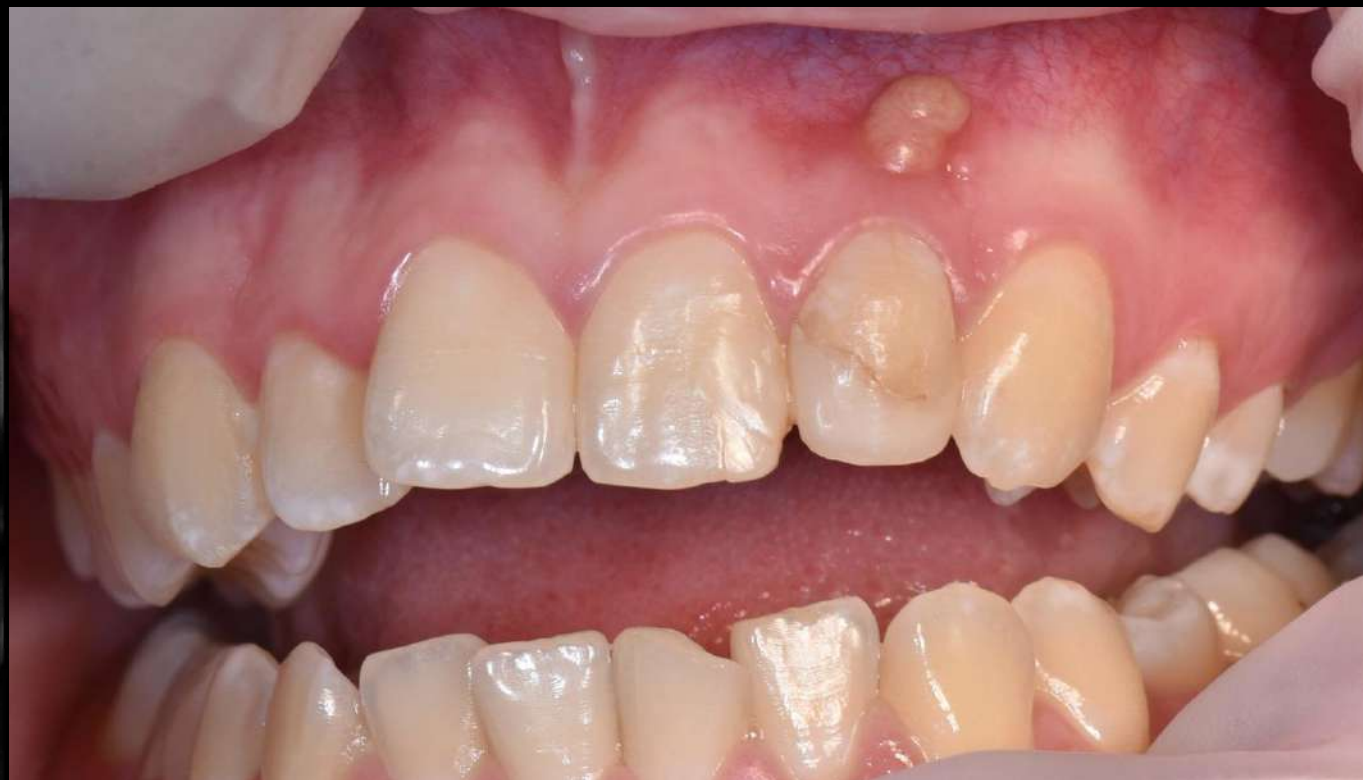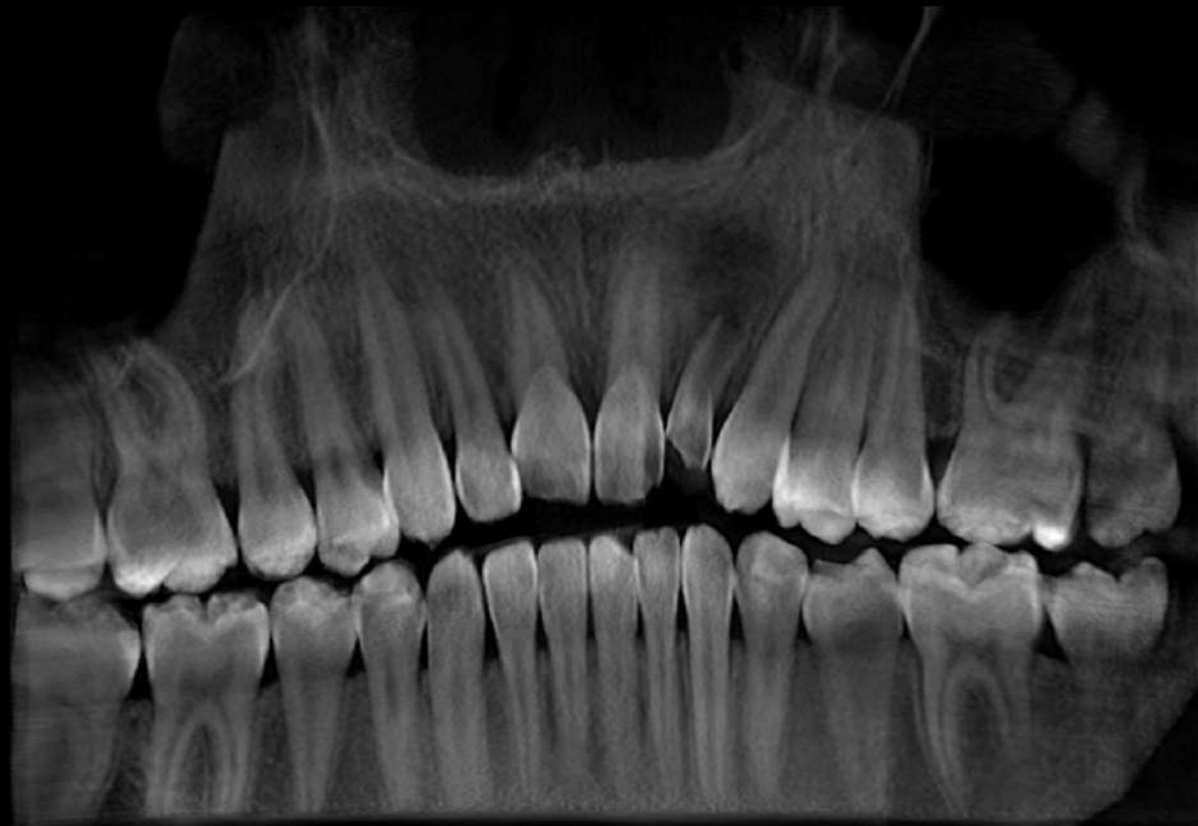Founder dental clinic  
„RADENT”

President-elect of the Association  
of Implantologists of  
Ukraine, regional director of ITI

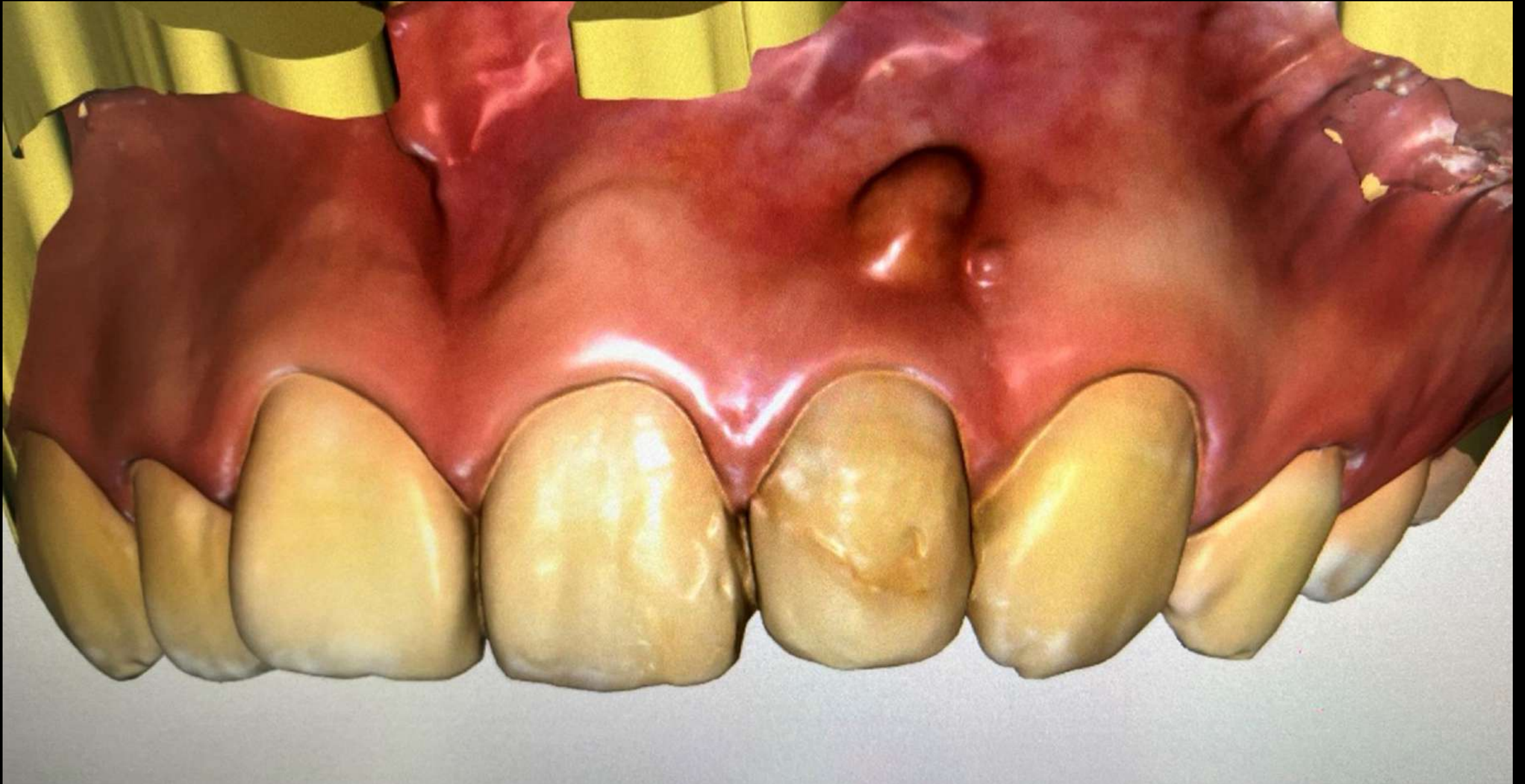Case 2



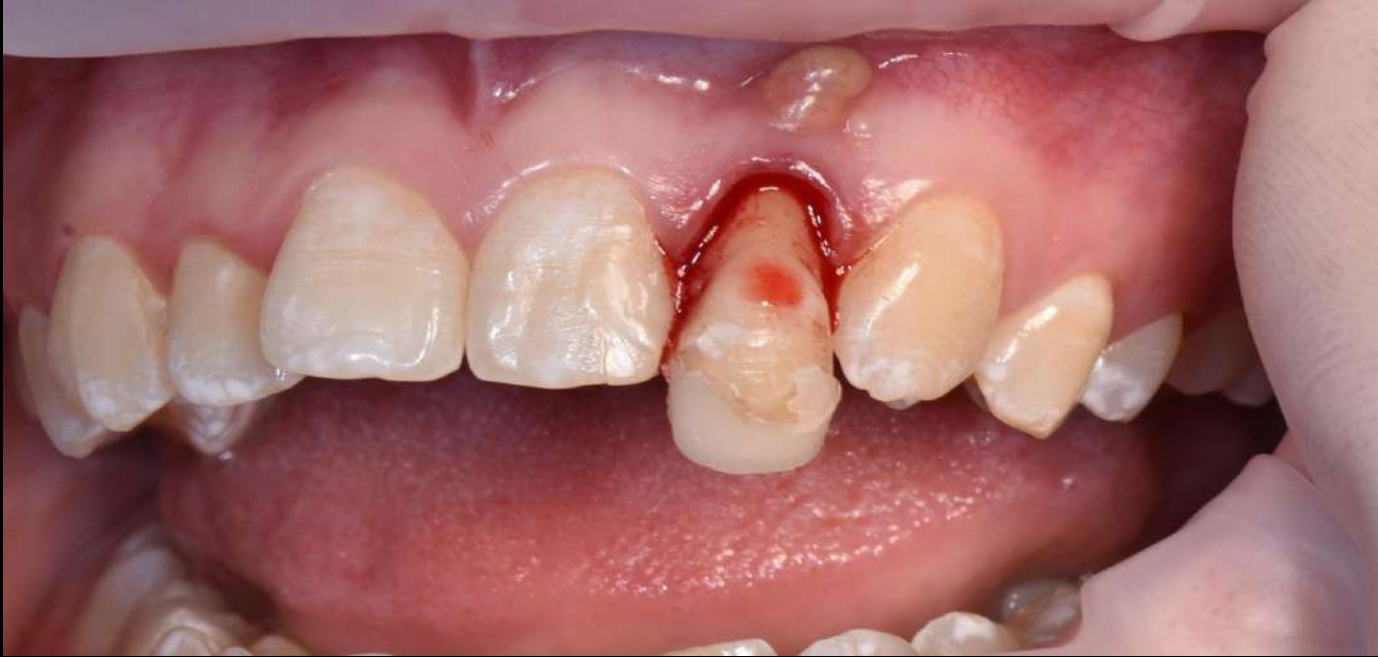# Initial situation



# Scan before dental implantation

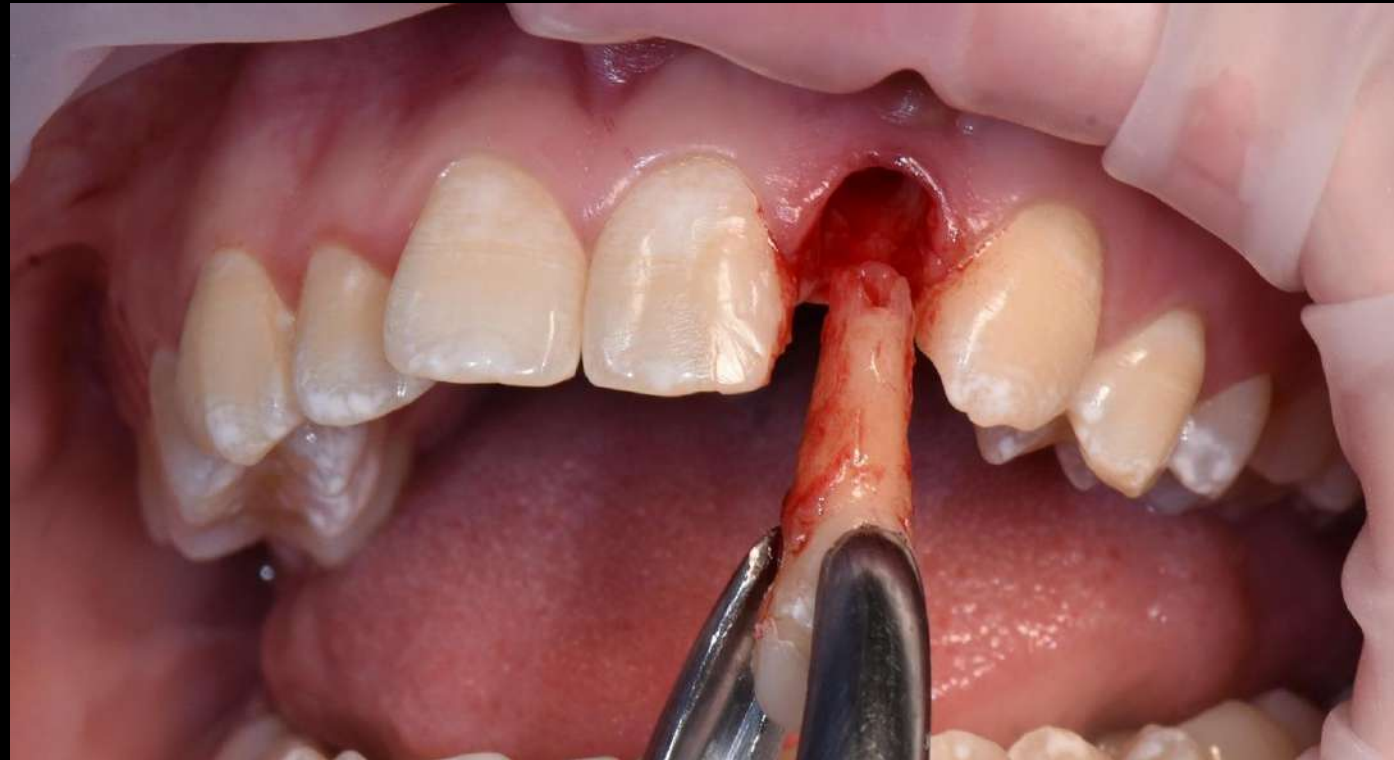




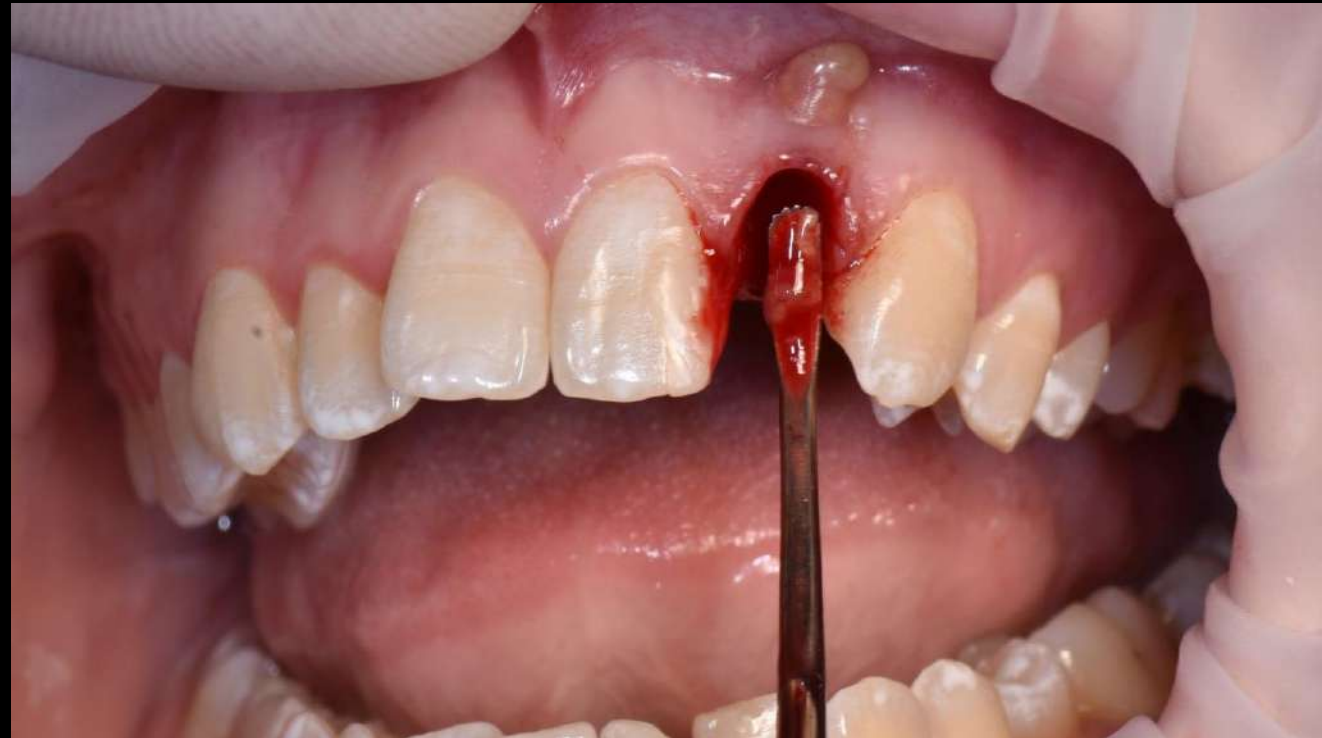
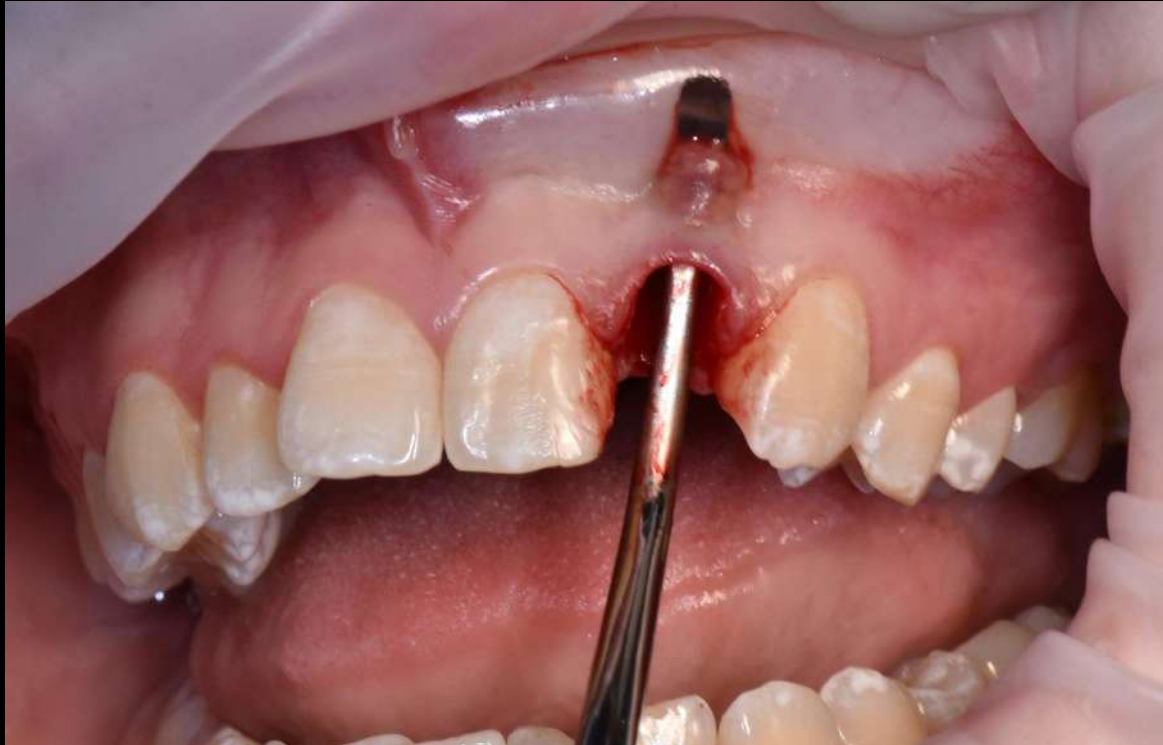Stage of tooth extraction

WITH MINIMAL TRAUMA TO THE TOOTH  
SOCKET

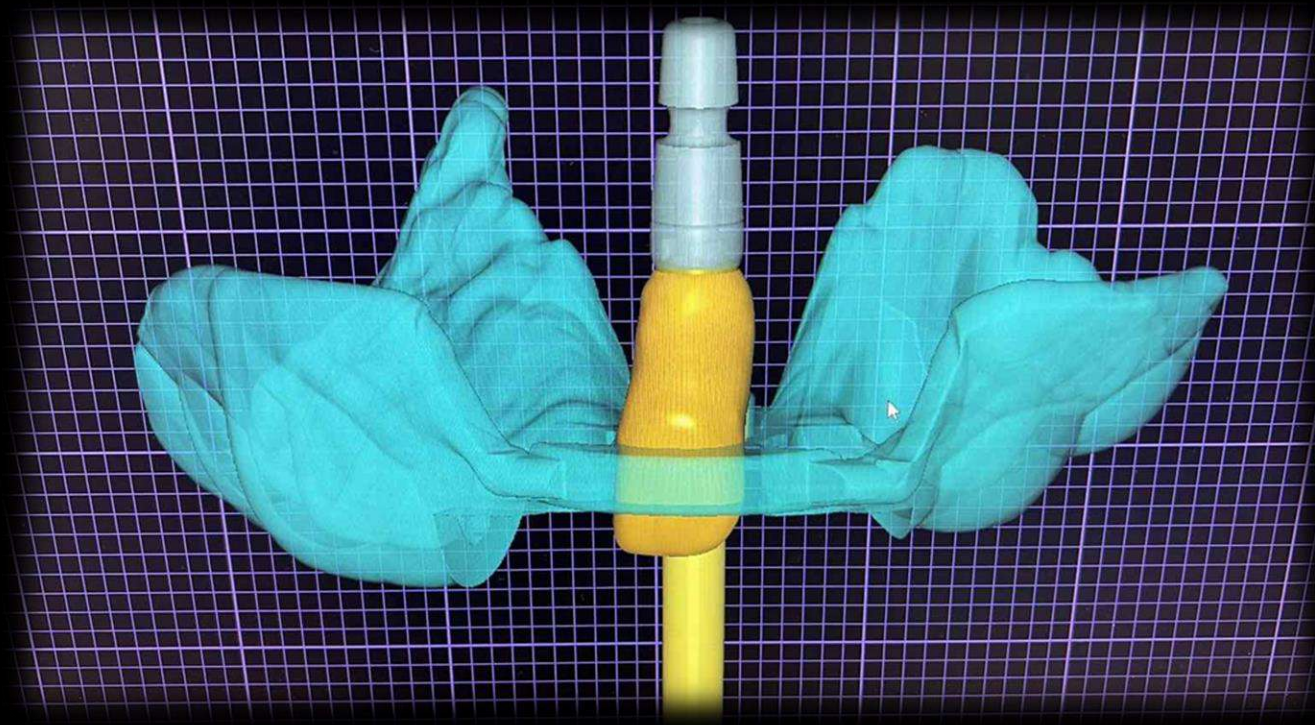


# Fenestration of the vestibule-apical cyst

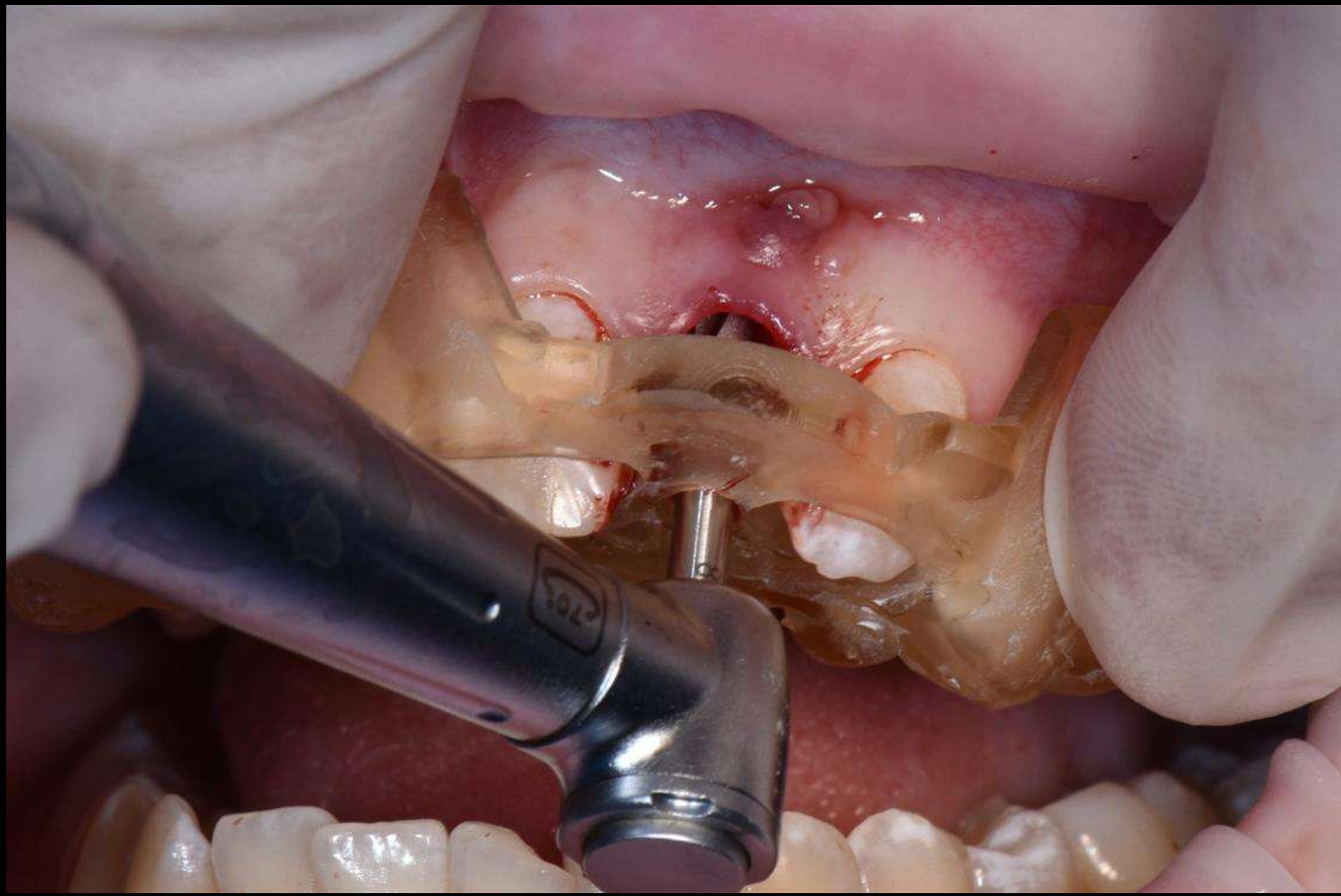




# PROJECT OF A TEMPORARY CROWN BEFORE IMPLANTATION

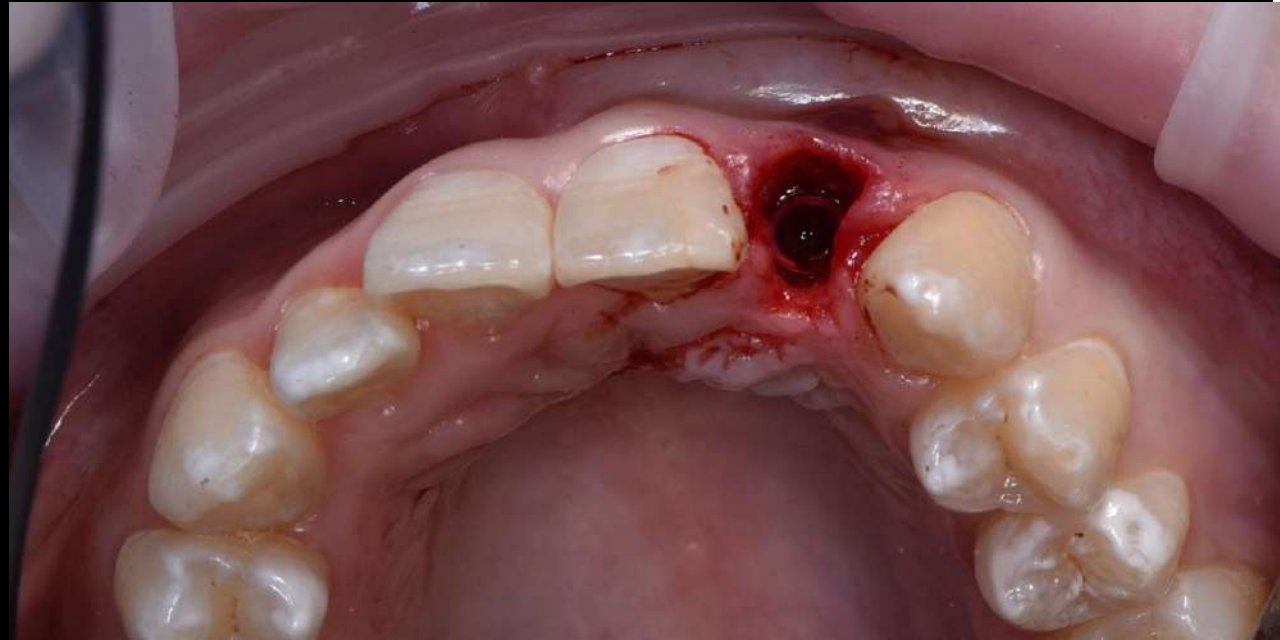
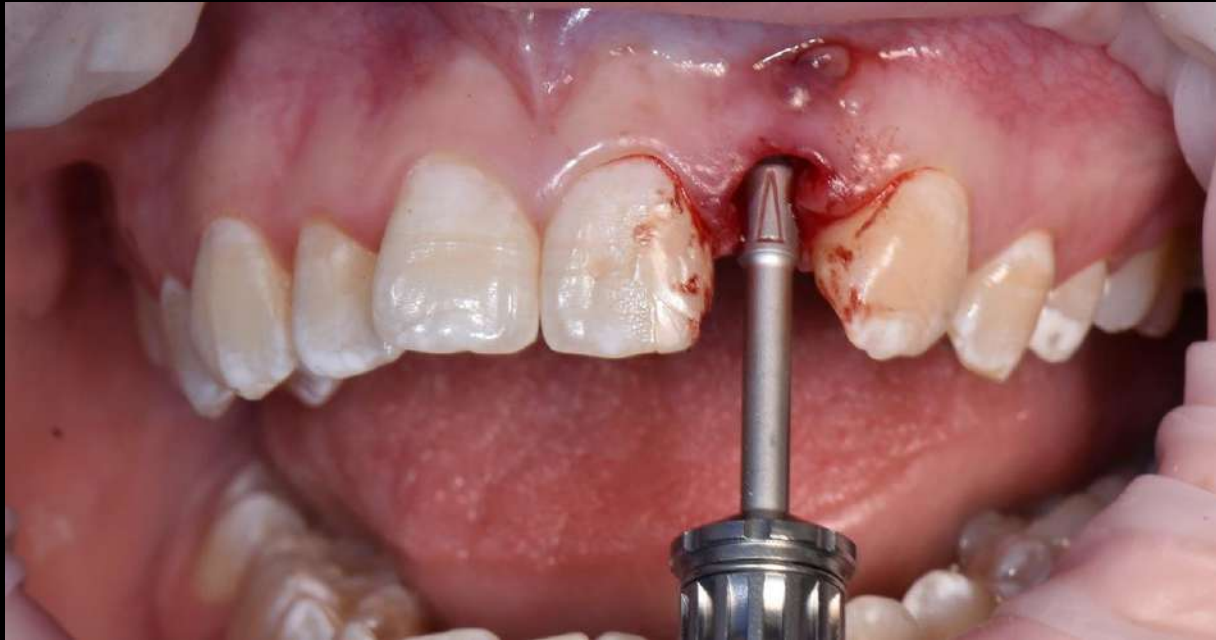

# NAVIGATION IMPLANTATION



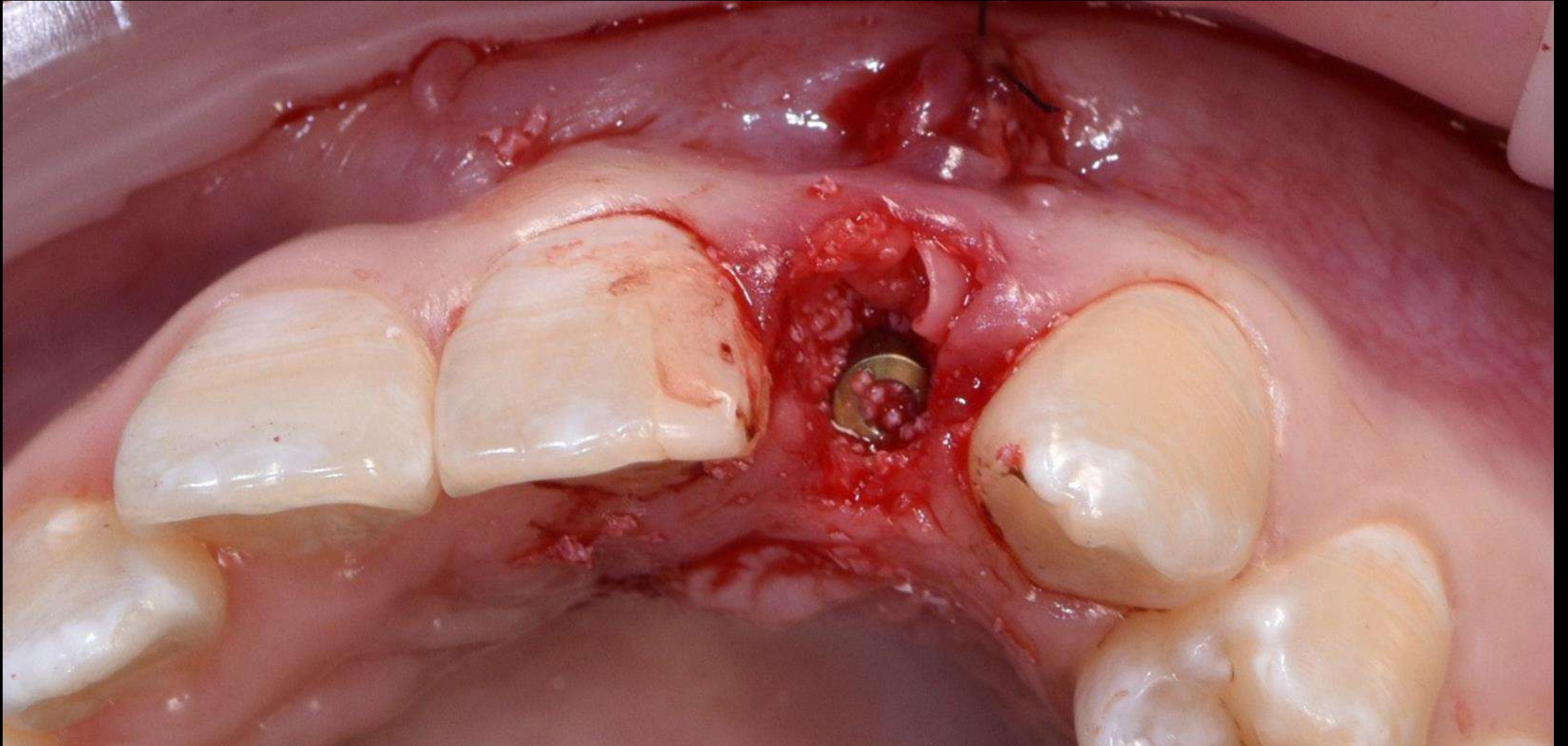


# Instalation of the implant in 3D position

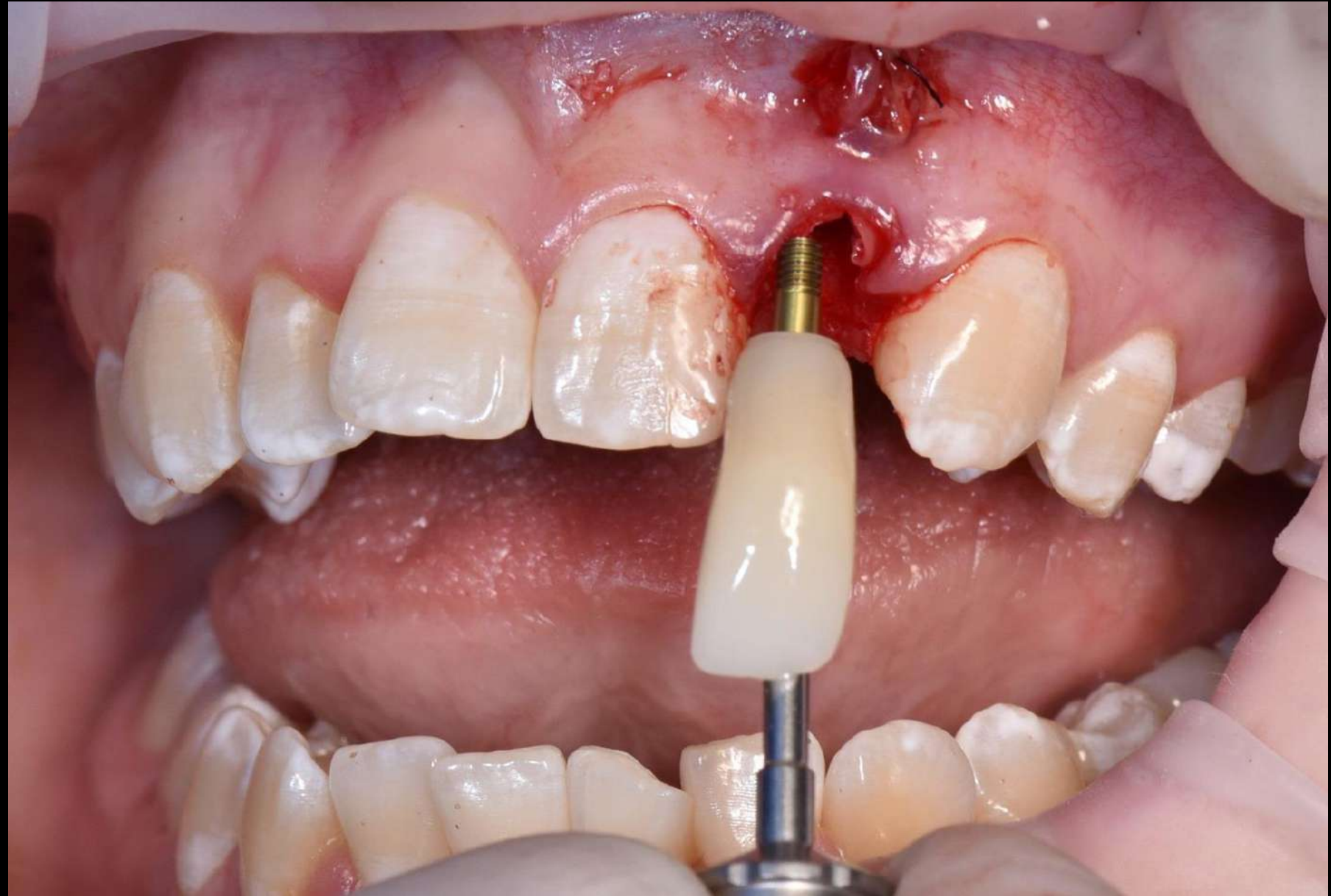
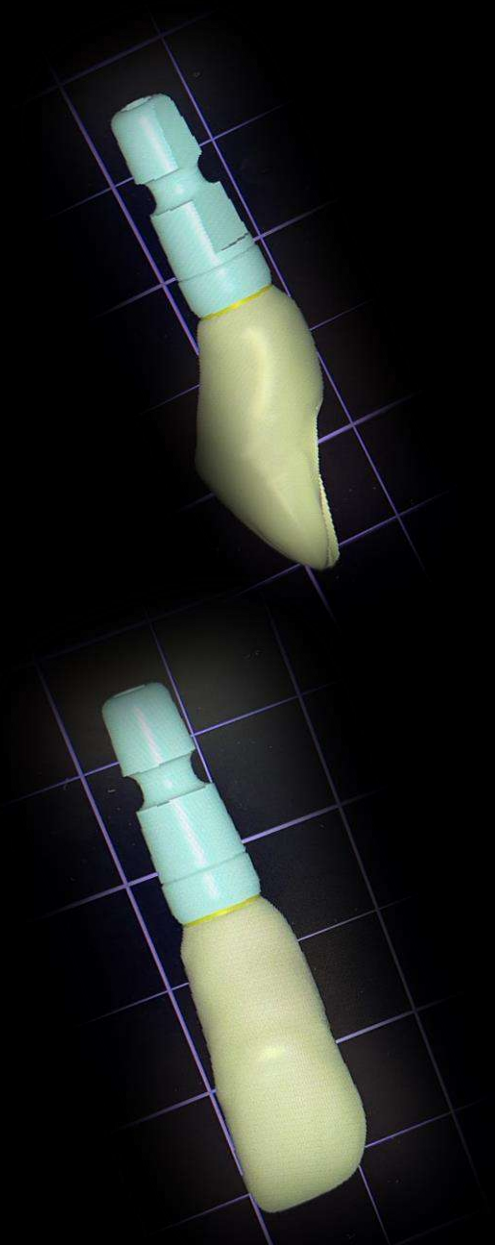




# DIRECTED BONE REGENERATION OF THE TOOTH SOCKET WITH PRF

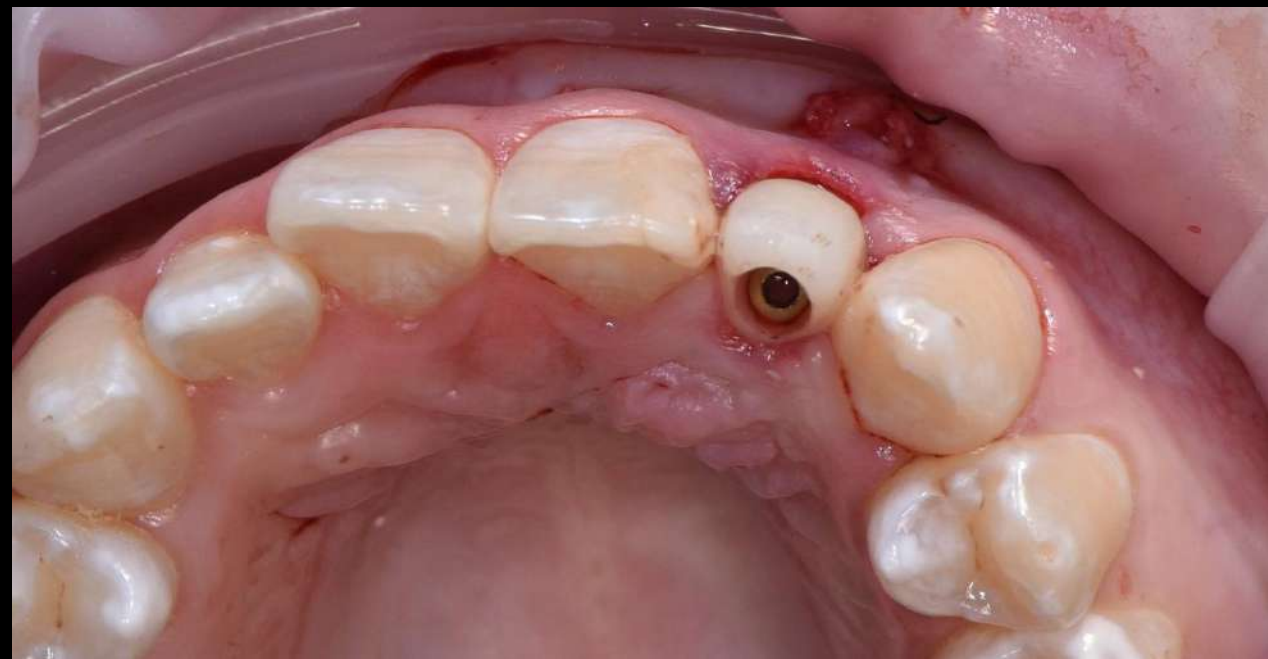
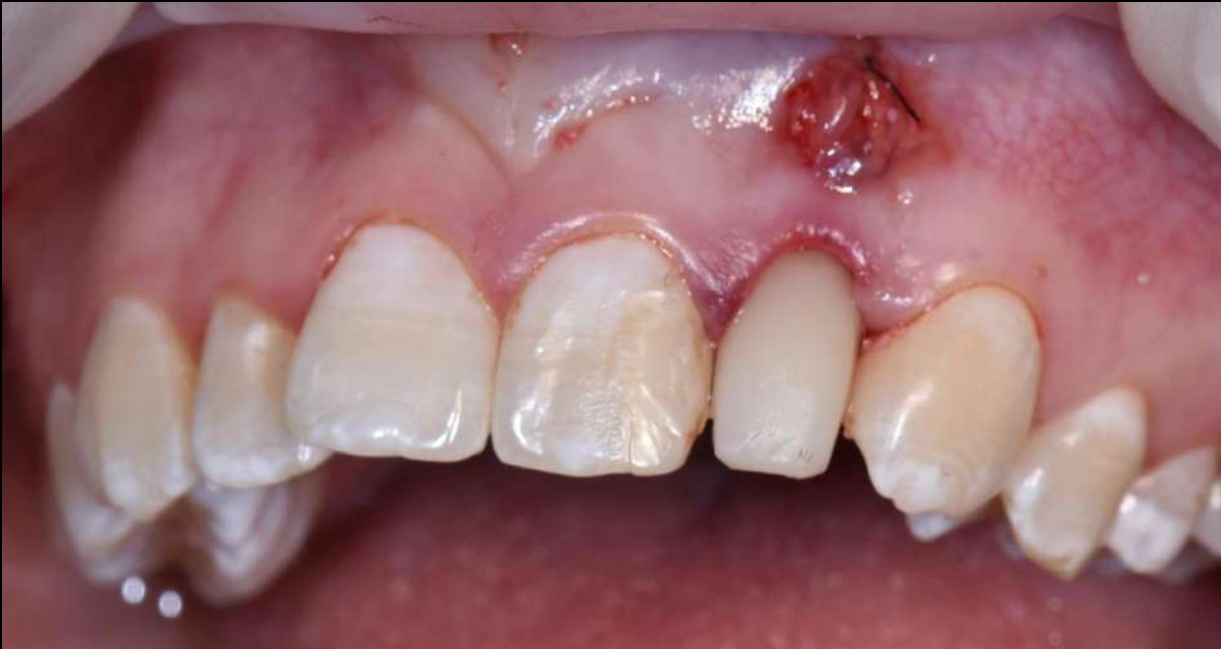

# IMMEDIAT INSTALATION OF TEMPORARY STRUCTURE MODELED BEFORE IMPLANTATION

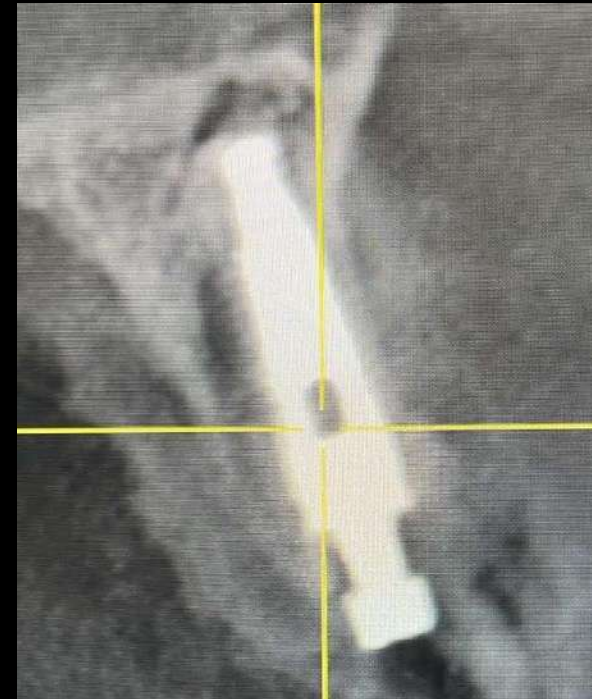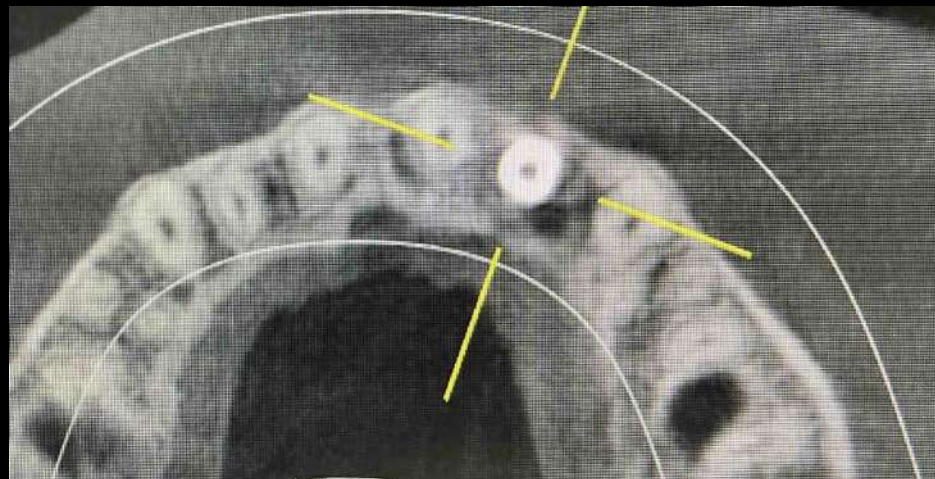
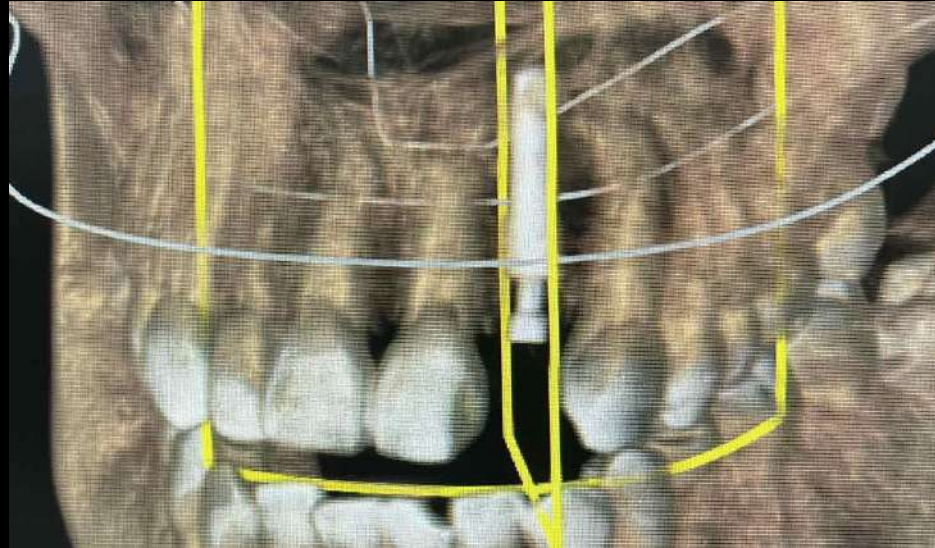

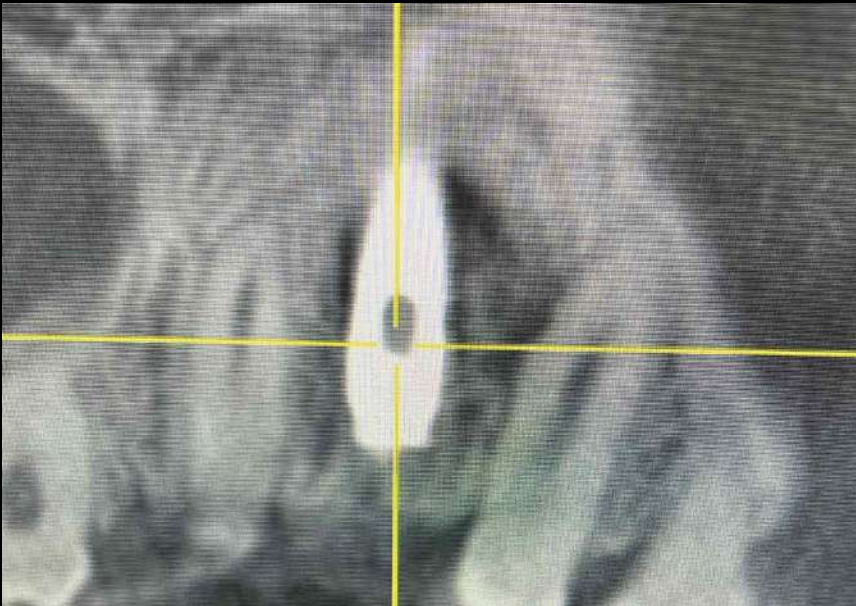


# Immediate loading-conditional screw fixation

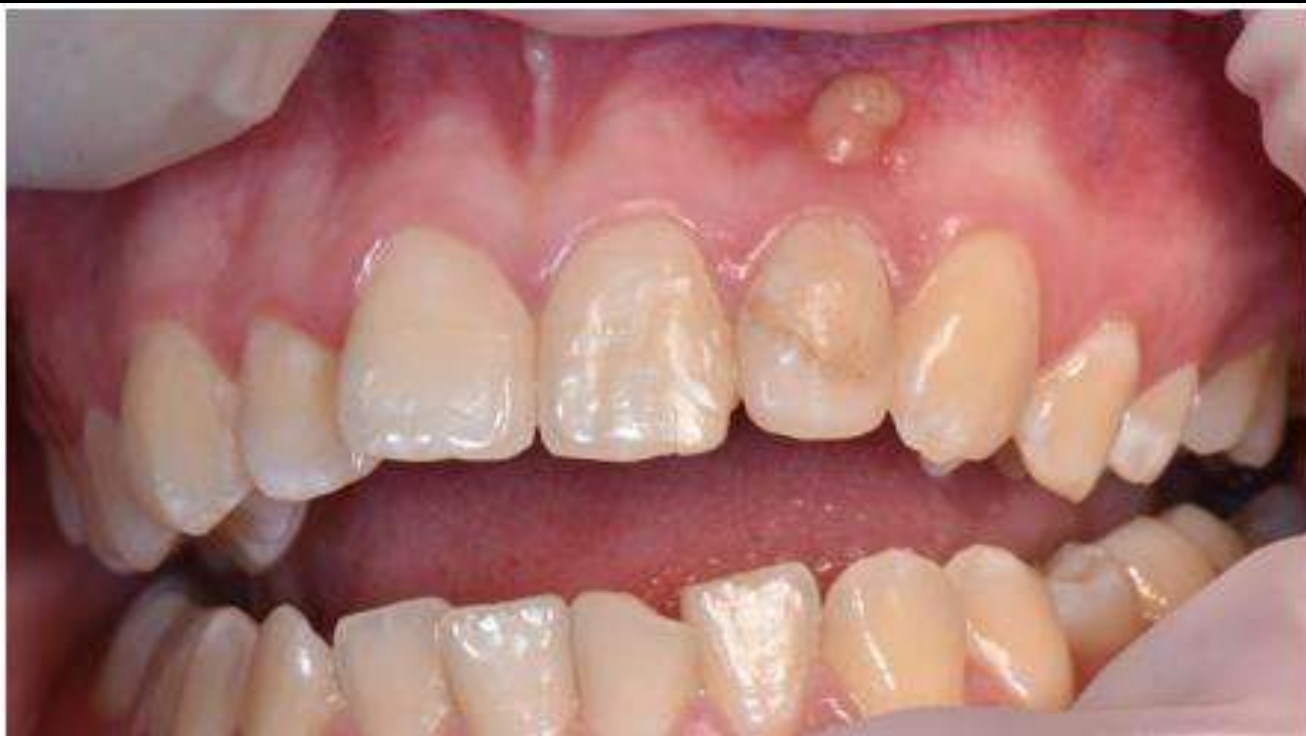

# X-Ray after dental implantation

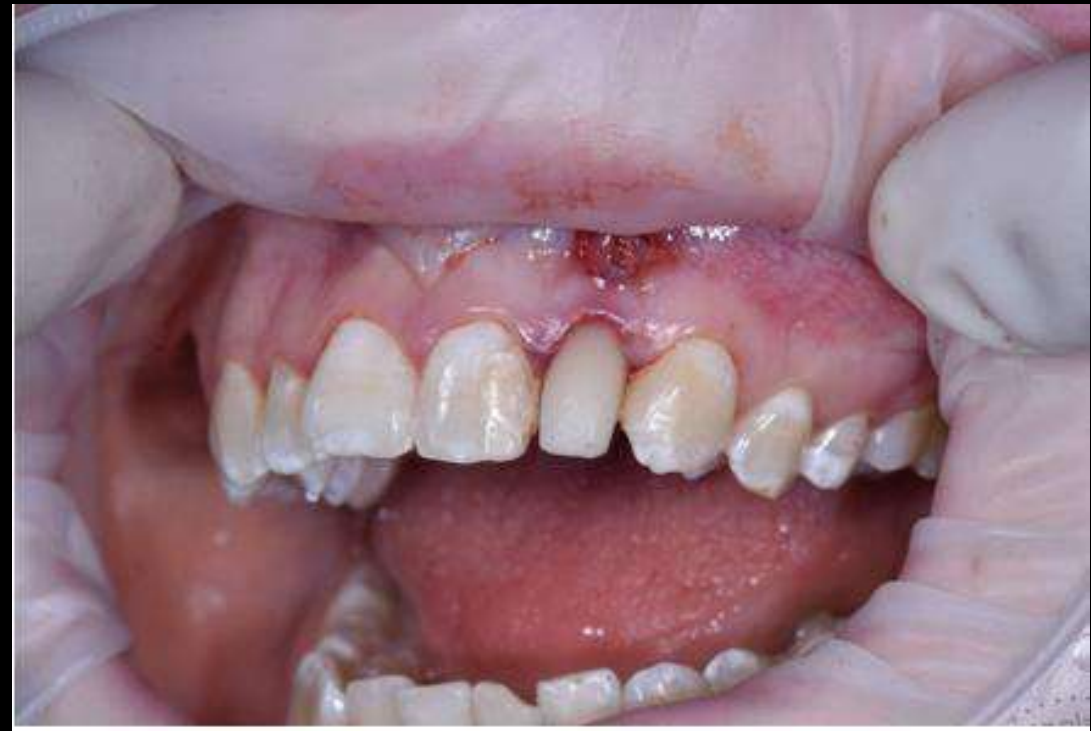



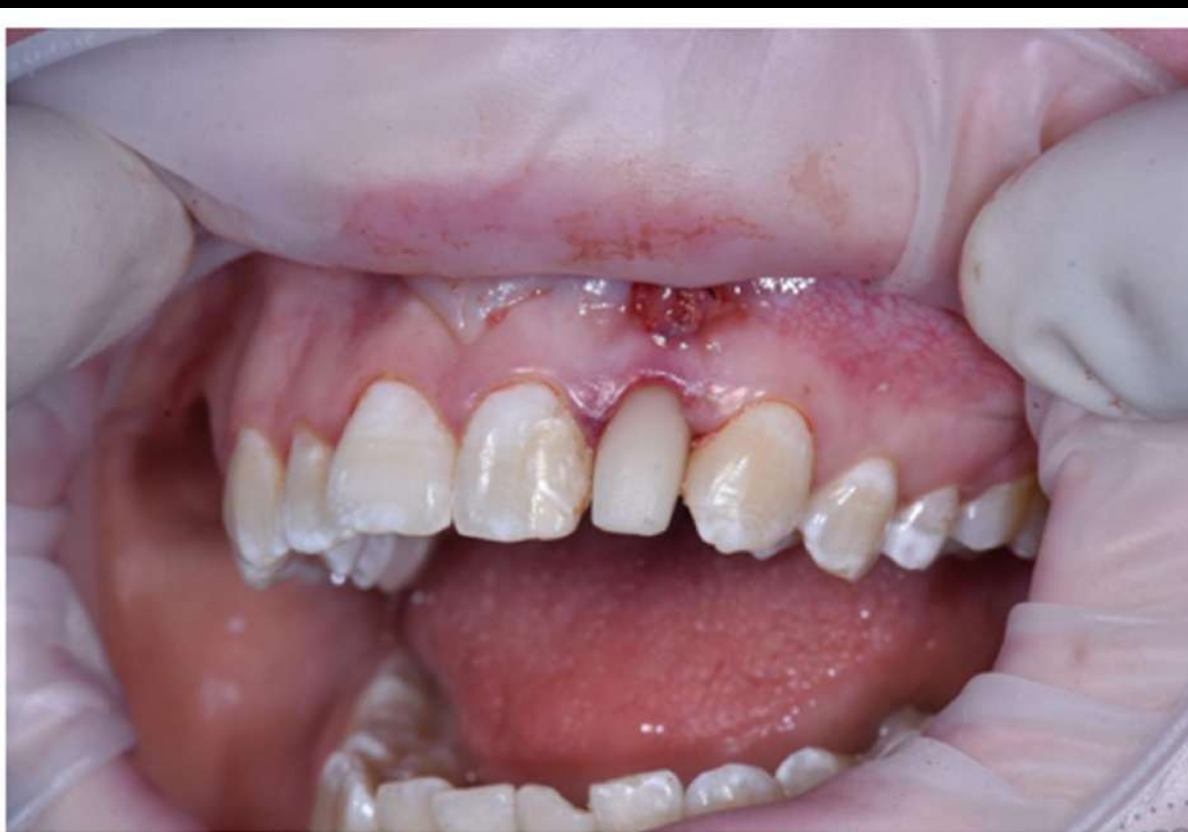BEFORE SURGERY IMPLANTATION



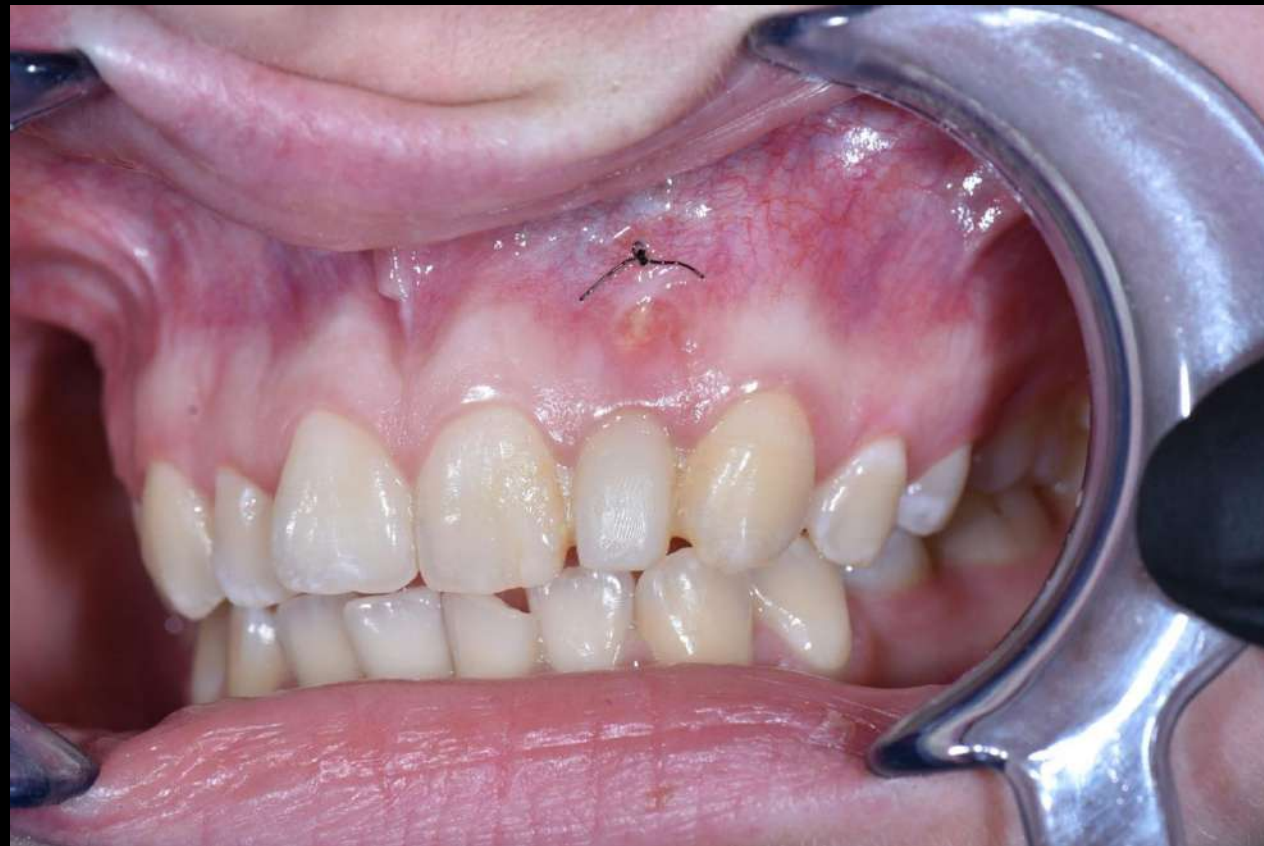AFTER SURGERY IMPLANTATION DAY



AFTER SURGERY IMPLANTATION DAY



15 DAYS AFTER DENTAL IMPLANTATION







matrix<sup>®</sup>x