



Healthy seniors aging in place - The impact of remote wound monitoring for seniors using multispectral imaging: a case series



Tracey Rickards*, Tracey Smith*, Surajudeen Shittu*, Chris Boodoo**, Karen Cross**
*Faculty of Nursing, University of New Brunswick, NB, Canada and **MIMOSA Diagnostics, Toronto, ON, Canada



Objective: To identify the benefits of incorporating a mobile multispectral imaging system in the care of seniors with lower extremity wounds

Background

There is an unprecedented increase in the rate of seniors who are living alone and in rural communities [1]. Vulnerable seniors are susceptible to decreased quality of life due to chronic illness and depression [2]. This is especially true for seniors with lower extremity wounds who live in rural communities as they often experience limited mobility and lack access to appropriate healthcare [3]. Such populations often have comorbidities, thus they require robust assessments of their wounds by in-person visits with specialists, and they are vulnerable to wound complications. The lack of access to such resources was further exacerbated by the COVID-19 pandemic. In response, a mobile client-centered footcare program was deployed in rural communities surrounding a mid-size city in New Brunswick, Canada. In this program, footcare was used a tool of engagement with the ultimate goal of supporting safe aging-in-place and improving access to healthcare needs using a mobile multi-disciplinary team approach and remote monitoring. As a part of this footcare, a mobile multispectral imaging device was incorporated to support the footcare nurses with comprehensive assessments of the lower extremity wounds.

Methods

This intervention study enrolled seniors 55 years and older (n=300) during the COVID-19 Pandemic between 2020-2022. A Registered Nurse and Social Worker initially assessed each senior, then continued home visits on a regular basis for eight months. Footcare included assessments using a mobile multispectral imaging device* measuring tissue oximetry and temperature, risk assessments using the mobile platform, inLow Diabetic Foot Risk screen, and physical assessments. Seniors at risk for lower extremity or wound complications continued to receive specialized healthcare services, including wound and vascular clinics. As this study is ongoing, we included four cases to depict our experience with the program.

Conclusions

- The deployment of an outreach footcare program using mobile multispectral imaging is essential to support healthy aging-in-place for seniors.
- The impact is even greater for seniors living with lower extremity wounds.
- Seniors living in rural areas receiving footcare, which includes the remote monitoring of tissue oximetry and temperature via mobile multispectral imaging and risk assessments, optimally benefit as seen through the improvement to their health and wellness outcomes.

Cases

Case 1 – BM301 – A 73-year-old man with type II diabetes and chronic diabetic ulcer. The individual's history included peripheral vascular disease, bilateral common iliac artery angioplasty with stents, claudication, hypertension, two coronary artery bypass graft surgeries, myocardial infarction, and ischemic heart disease. He presented with a chronic diabetic ulcer that persisted since 2020 on the medial aspect of the right hallux. On May 29th, the individual went to the emergency room on the recommendation of the footcare nurse due to purulent drainage from the wound. During enrollment in the program, the individual was referred to a vascular surgeon for further assessment given his medical history where he had his wound debrided. The mobile multispectral imaging device helped assess the vascular health of the individual given his medical history during his enrolment in the program.

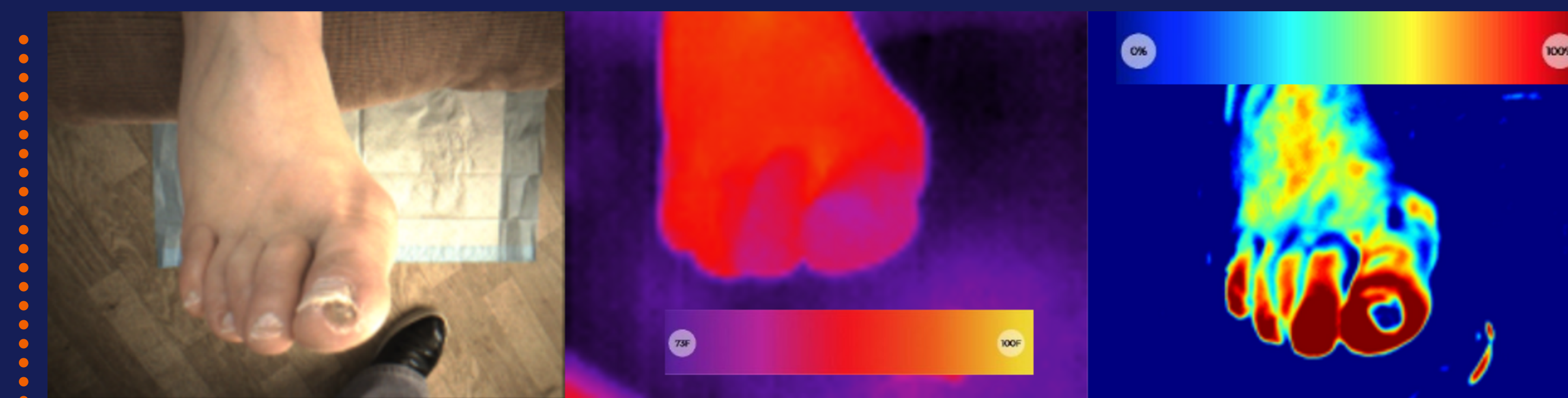


FIGURE 1 – Visible light, temperature, and tissue oximetry images from initial visit on April 5th (Images shows that the foot seems to be well perfused and not at immediate risk).




FIGURE 2 – Visible light, temperature, and tissue oximetry images from follow up visit on August 29th (The images show that the foot and wound progressing well and no cause for concern).

Case 2 – HP317 – A 64-year-old woman with type I diabetes and a chronic diabetic ulcer. The individual's history included left hallux partial amputation, cellulitis, diabetic retinopathy, diabetic neuropathy, hypertension, and hypothyroidism. She presented with a chronic diabetic ulcer that persisted since 2021 on the plantar surface of right forefoot distal to right hallux and is regularly followed by an infectious disease specialist. In March 2022, there was no presence of osteomyelitis. Given the chronic nature of the wound, she was referred and enrolled into the program on April 11th, 2022. Given the images and full assessment, the individual was deemed high risk and maintained regular follow-up with the infectious disease specialist. In May 2022, the wound was tested positive for Staphylococcus aureus and Streptococcus agalactiae and was prescribed oral antibiotics. It was also identified an increase in hypertrophy callus build up requiring extensive debridement. She began to receive at-home wound care three times a week including debridement and dressing changes. With support of the mobile wound care nurses and offloading, it can be seen in the Figure 4 that the wound has progressed well.

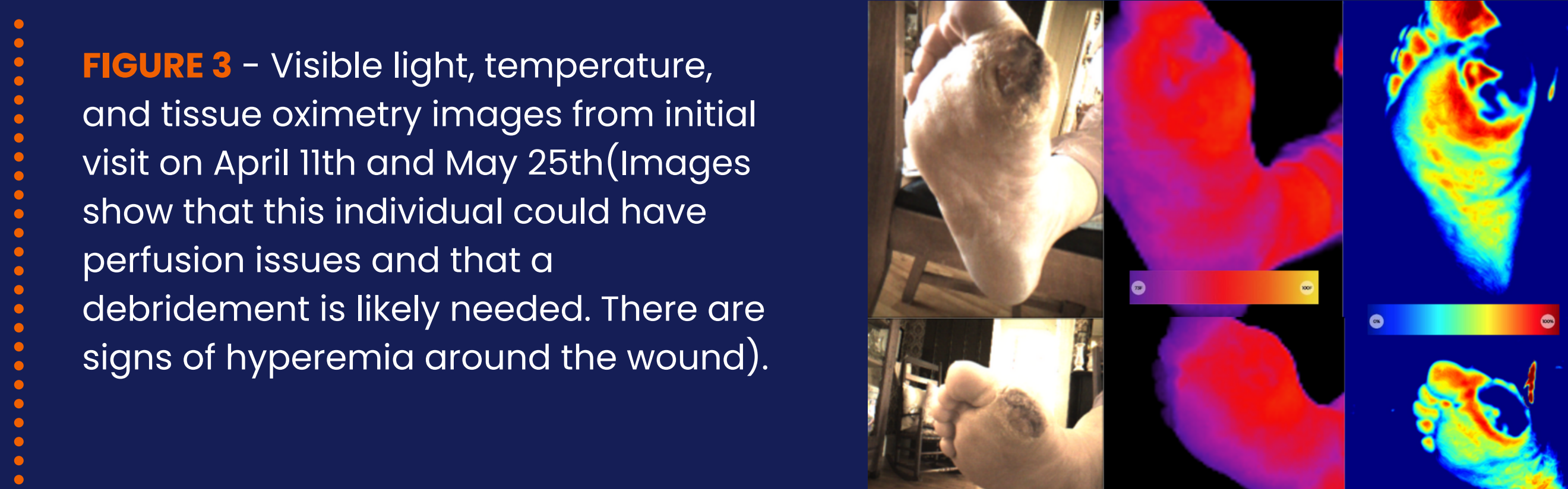


FIGURE 3 – Visible light, temperature, and tissue oximetry images from initial visit on April 11th and May 25th (Images show that this individual could have perfusion issues and that a debridement is likely needed. There are signs of hyperemia around the wound).

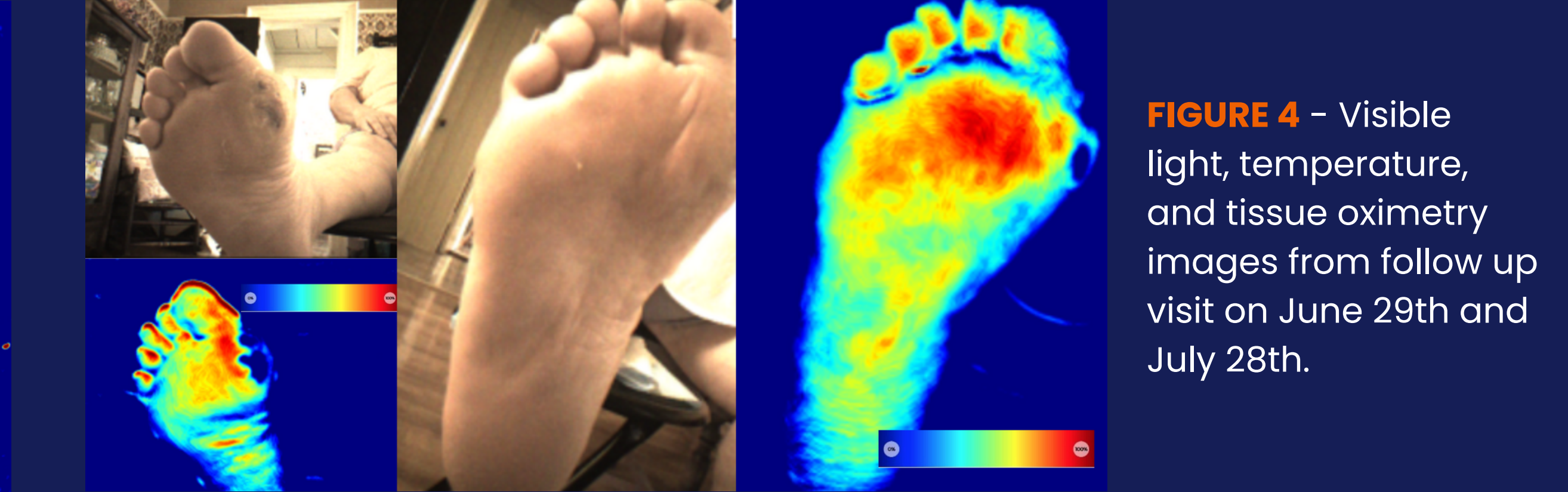


FIGURE 4 – Visible light, temperature, and tissue oximetry images from follow up visit on June 29th and July 28th.

Case 3 – EB364 – A 58-year-old man with type II diabetes and chronic diabetic ulcer. The individual's history included end stage renal failure (2016) with hemodialysis three times a week, heart attack (non-STEMI May 2021), atrial flutter, angina, coronary artery disease, hyperkalemia, necrotizing fasciitis of abdomen (2021), hypertension, dyslipidemia, chronic back pain, diabetic neuropathy, recurrent right leg cellulitis, gout, restless leg syndrome, severe osteoarthritis in right knee, sleep apnea, right arm AV fistula for hemodialysis. From January 26th, 2022 to February 24th, 2022, this individual was hospitalized due to necrotizing skin soft tissue infection on the lateral aspect of his left midfoot, which started as a blister in December 2021. Once discharged, this individual attended monthly follow up visits at the wound care clinic at the hospital. On June 23rd, the individual was enrolled into the program and received at home foot care along with social services. The individual continued to receive at home support for wound care and foot care while also attending visits to a hospital wound care clinic. With the continued intervention of the mobile nurses and a family member, it can be seen in the figures that the wound has progressed well, thus dressing changes were discontinued August, 30th.

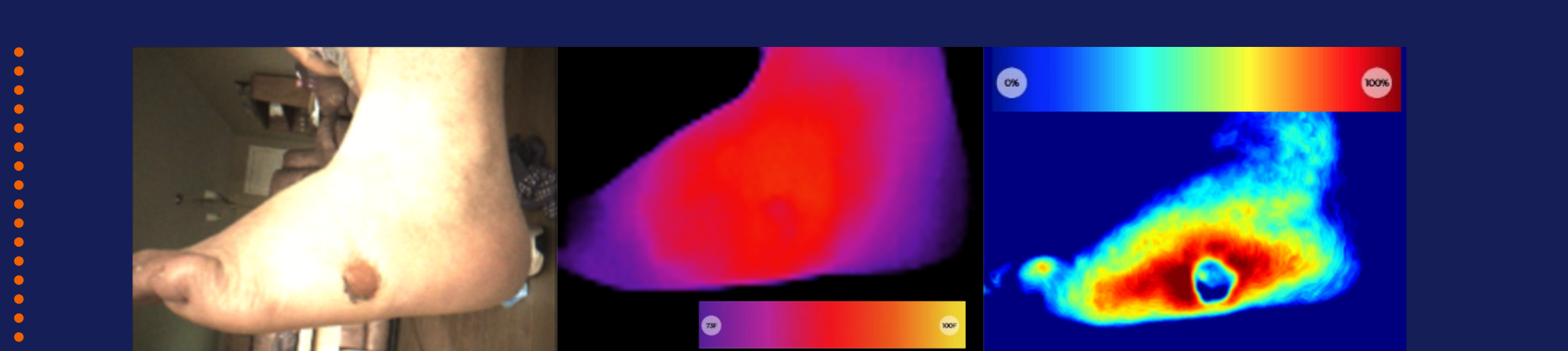


FIGURE 5 – Visible light, temperature, and tissue oximetry images from initial visit on June 23rd (Images show that this individual likely has perfusion issues and with signs of hyperemia around the wound.)

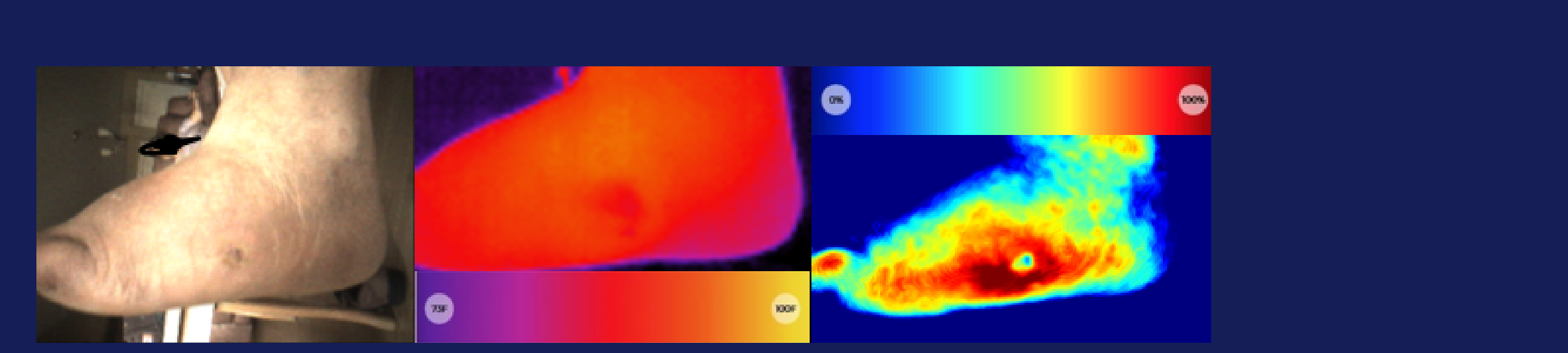


FIGURE 6 – Visible light, temperature, and tissue oximetry images from follow up visit on September 27th (Images shows that the wound is progressing well.)

Case 4 – HM351 (Healthy Feet) – A 70-year-old woman who is non-diabetic and has no active wounds. The patient's history included insomnia and caregiver strain. This individual was enrolled onto the program on June 1st to provide social services.

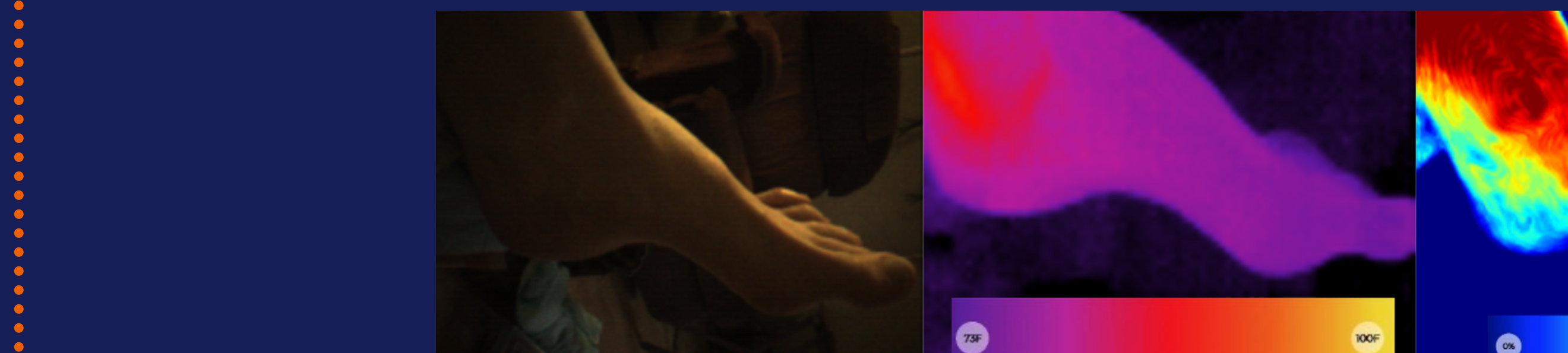


FIGURE 7 – Visible light, temperature, and tissue oximetry images from visit on September 22nd



This program was funded by the Healthy Seniors Pilot Project

Bibliography

1. GNB (2017). We are all in this together: An aging strategy for New Brunswick. Fredericton, NB: Province of New Brunswick.
2. Fiest, K. M., Currie, S. R., Williams, J. V. A., & Wang, J. (2011). Chronic conditions and major depression in community-dwelling older adults. *Journal of Affective Disorders*, 131, 172-178. Doi: 10.1016/j.jad.2010.11.028
3. Rickards, T., & Cornish, T. (2018). Reaching out to diabetic soles: Outreach foot care pilot project. *SAGE Open Med*, 6, 1. doi:10.1177/2050312118820030
4. Hill, J. (2017). Why supporting patients to self-manage their diabetes in the community is important. *British Journal of Community Nursing*, 22(11), 550. doi:10.12968/bjcn.2017.22.11.550
5. Elliott, J. (2015). Advocating for diabetic foot care change in Canada. *Diabetic Foot Canada*, 3(1), 9-10.

*MIMOSA Pro. MIMOSA Diagnostics Inc.