

# Innovating One-Step Grafting Technique for Implant Preparation

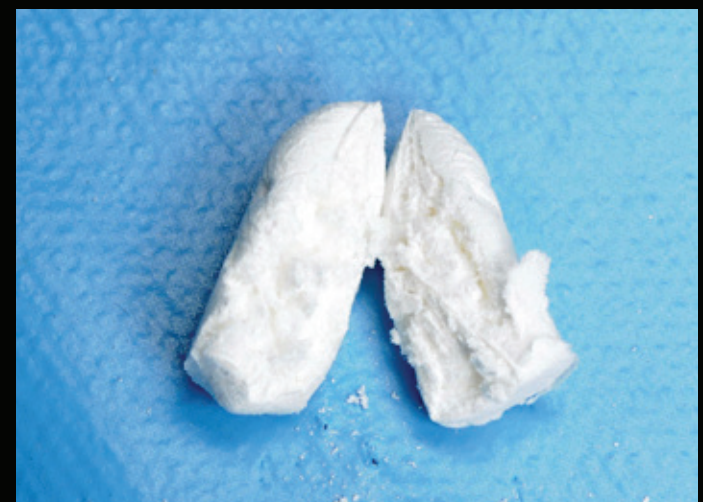
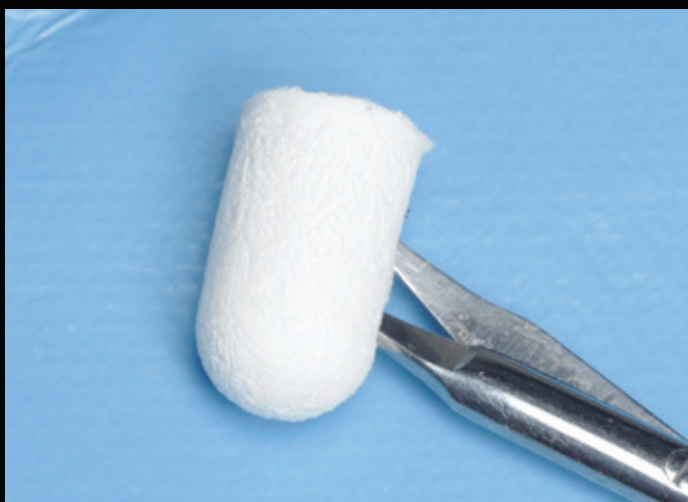
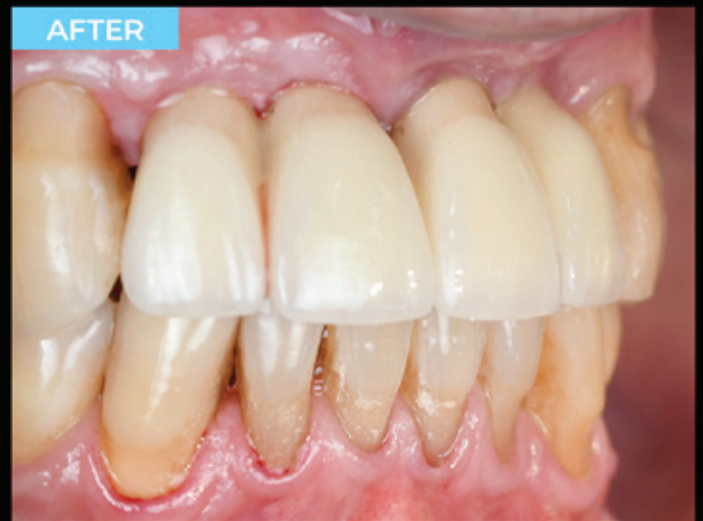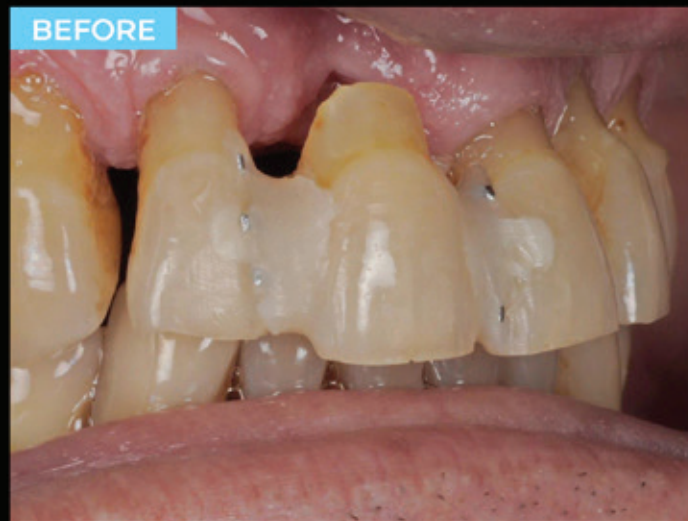## CLINICAL CASE

by **Dr. Miroshnik Vladislav DMD**  
Specialist in aesthetic dentistry,  
36 years of practice.  
Ashdod, Israel

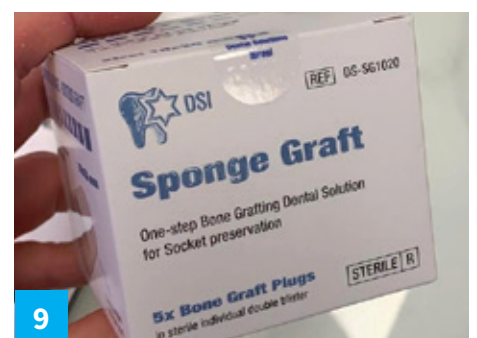
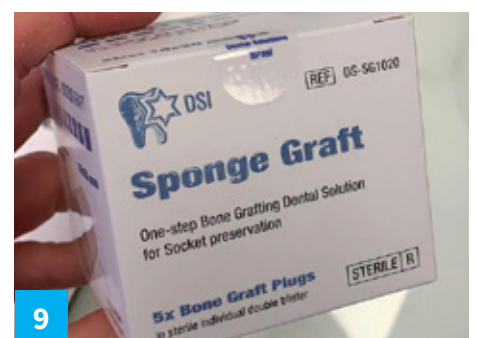
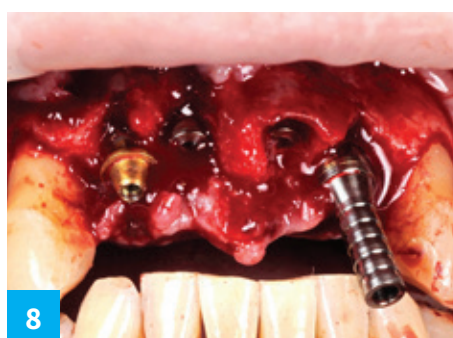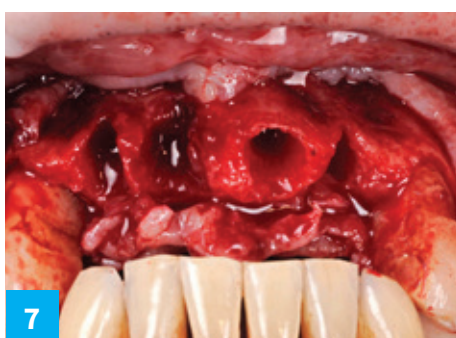
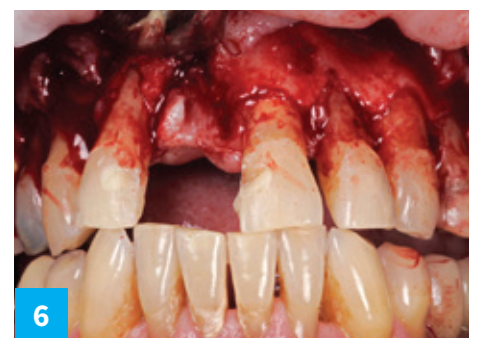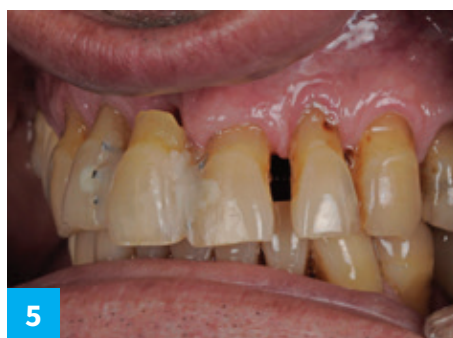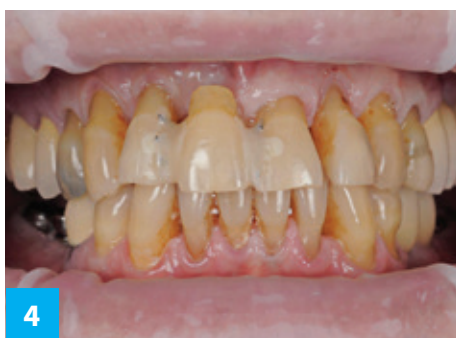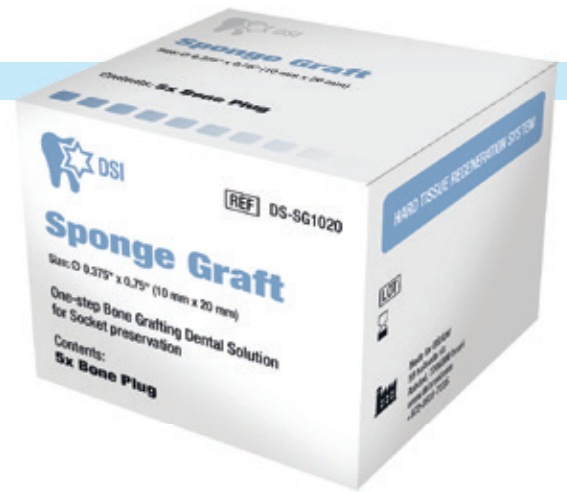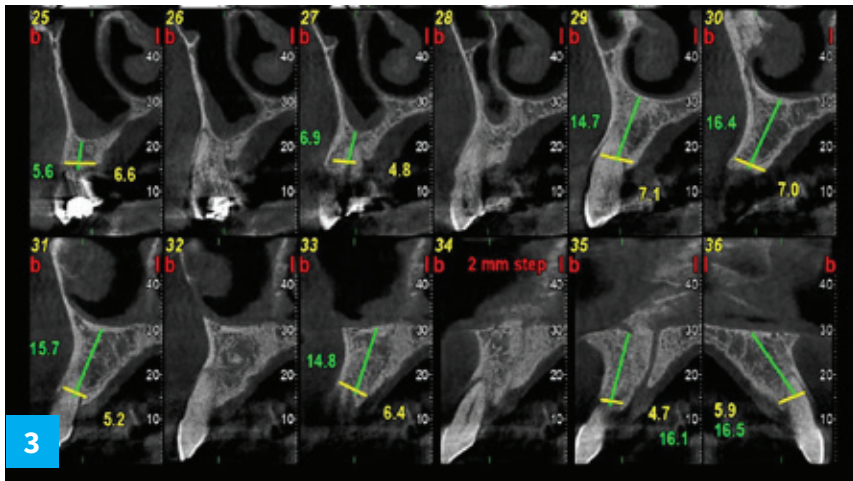
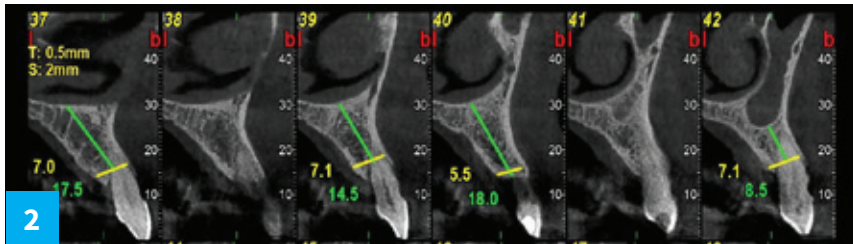
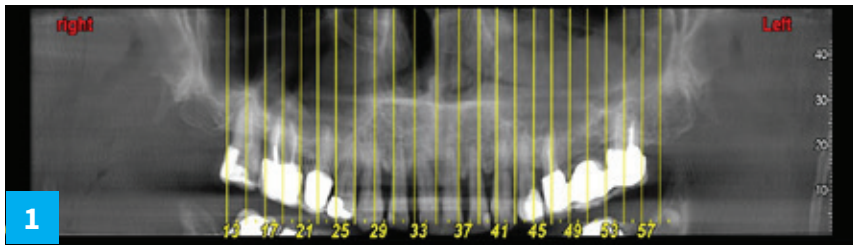
### Material and Method

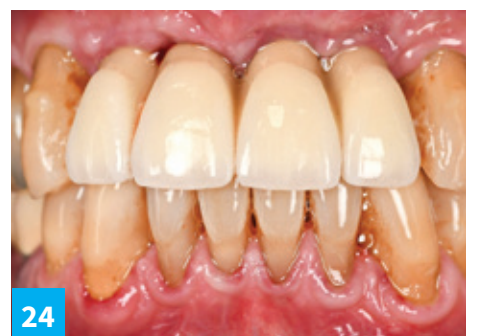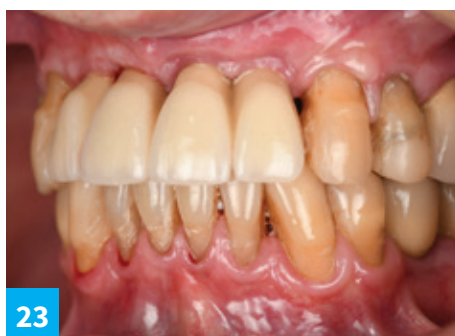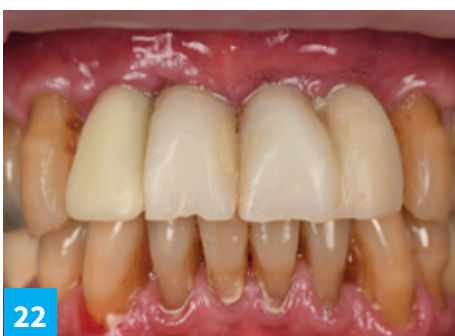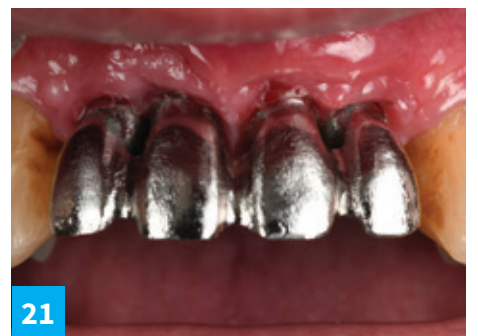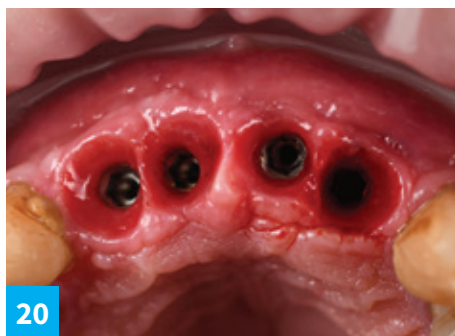
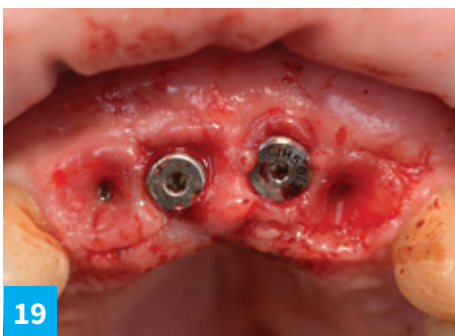
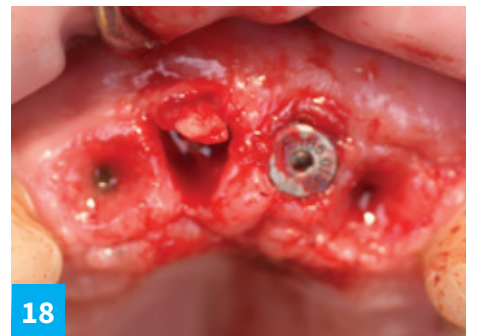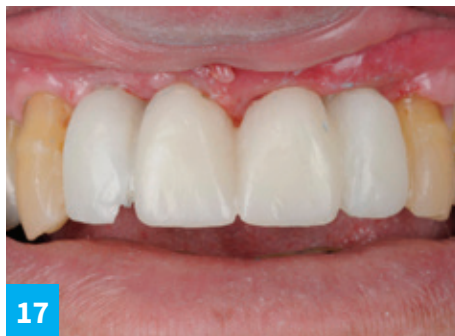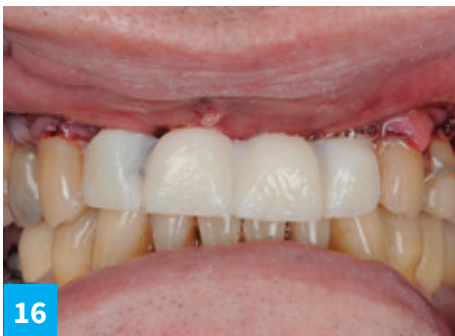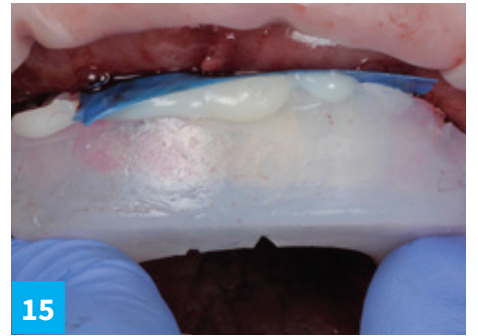
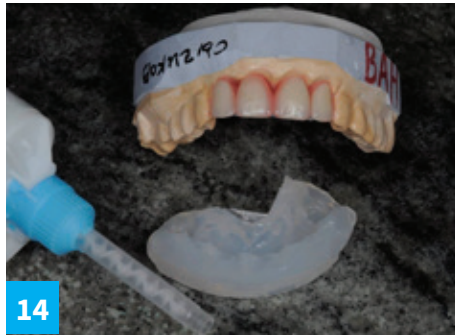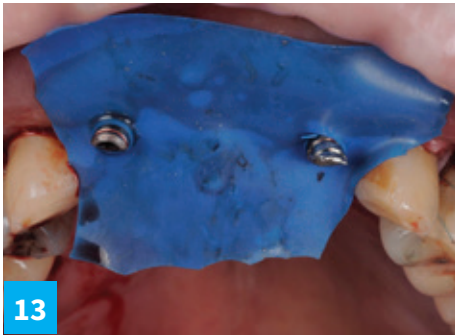
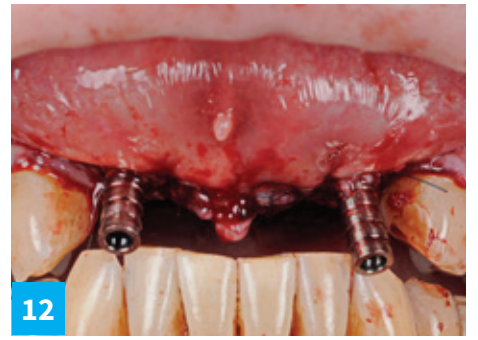
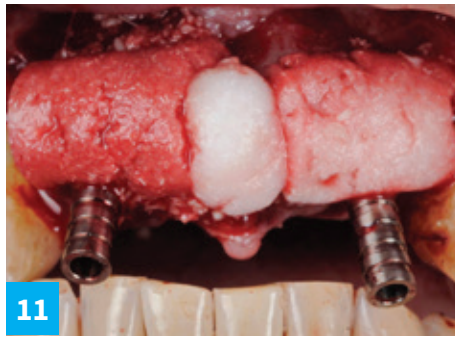
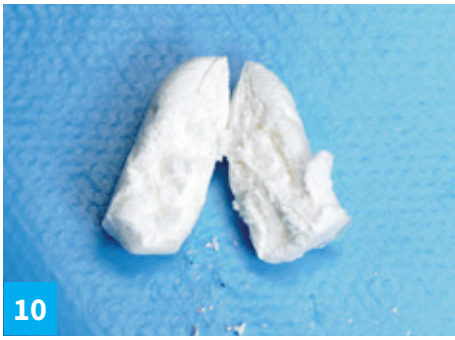Vertical and horizontal ridge  
augmentation using DSI SpongeGraft  
with immediate implant placement.



# CLINICAL CASE BY Dr. Miroshnik Vladislav DMD

## New bone formation with DSI SpongeGraft





# Post-op CT

