

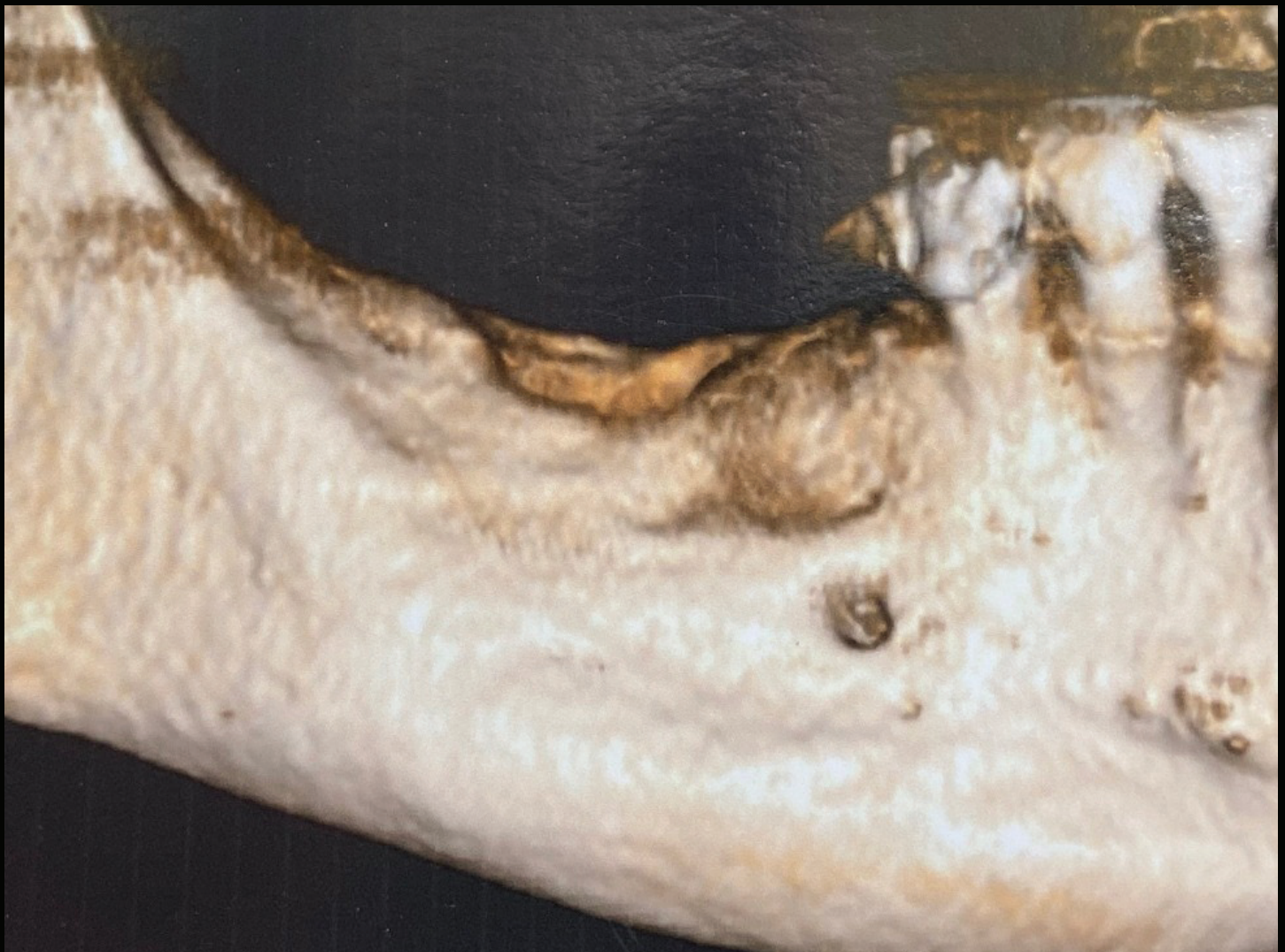
Lateral ridge augmentation with simultaneous implant placement



CLINICAL CASE

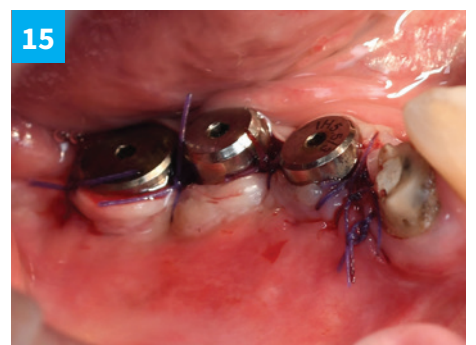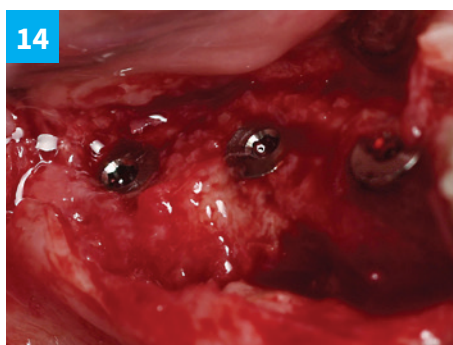
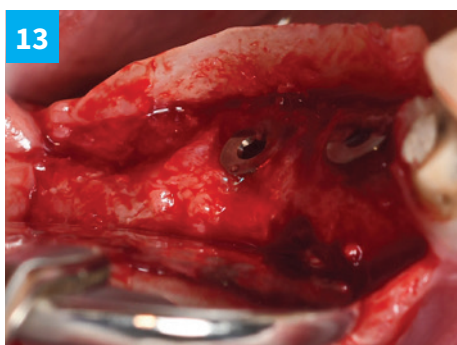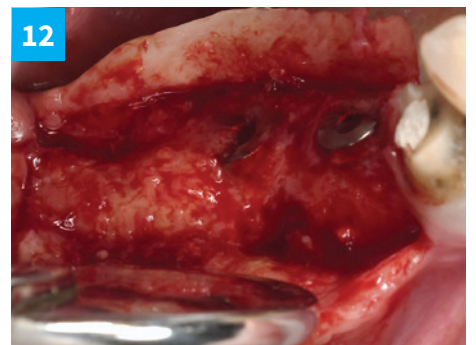
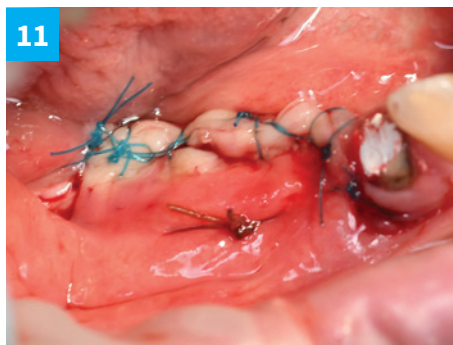
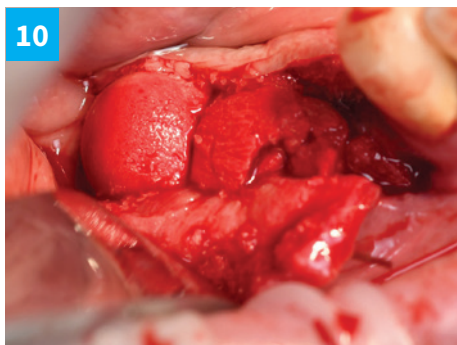
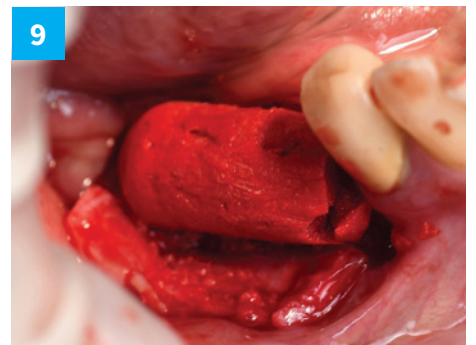

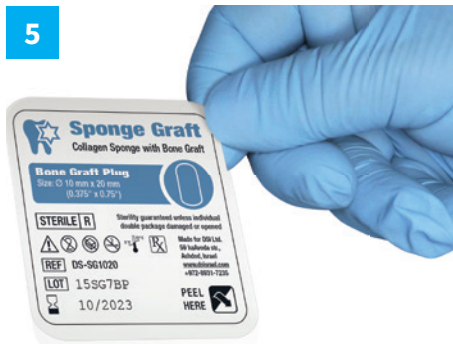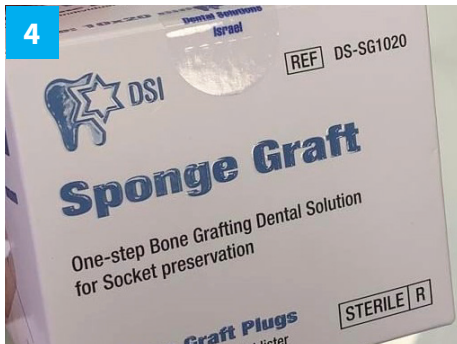
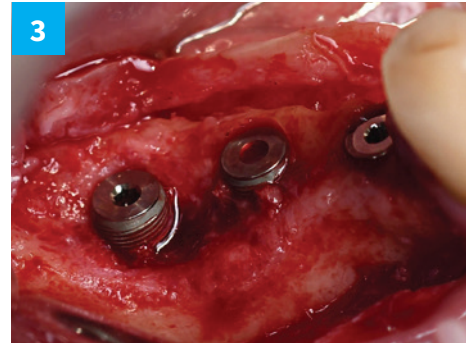
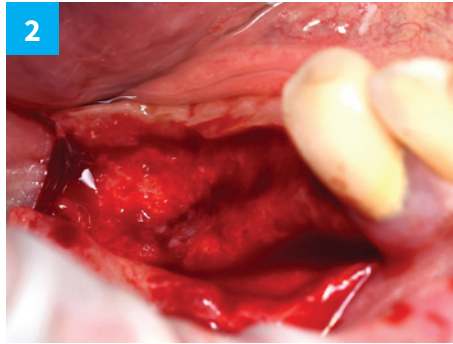
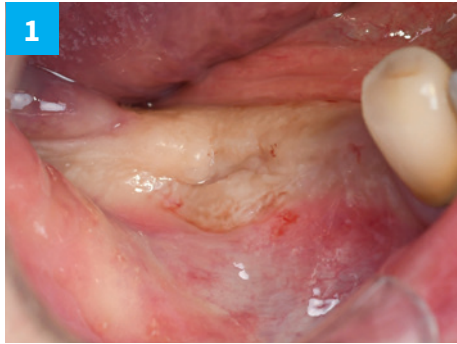by **Dr. Miroshnik Vladislav DMD**
Specialist in aesthetic dentistry,
36 years of practice.
Ashdod, Israel

Material and Method:
using DSI Sponge Graft as a bone filler –
without a barrier membrane.

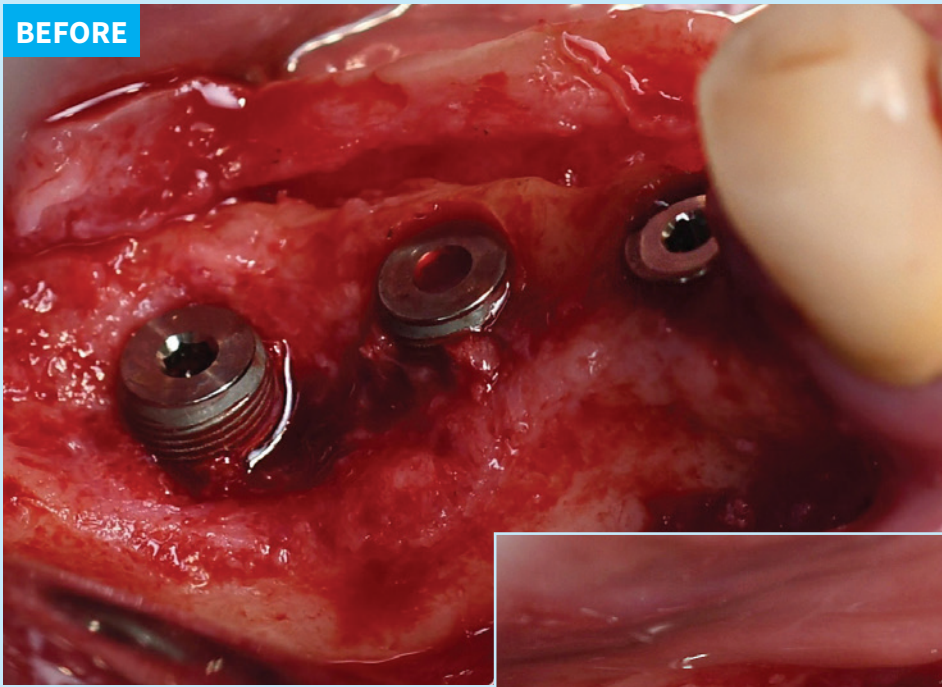


CLINICAL CASE BY Dr. Miroshnik Vladislav DMD

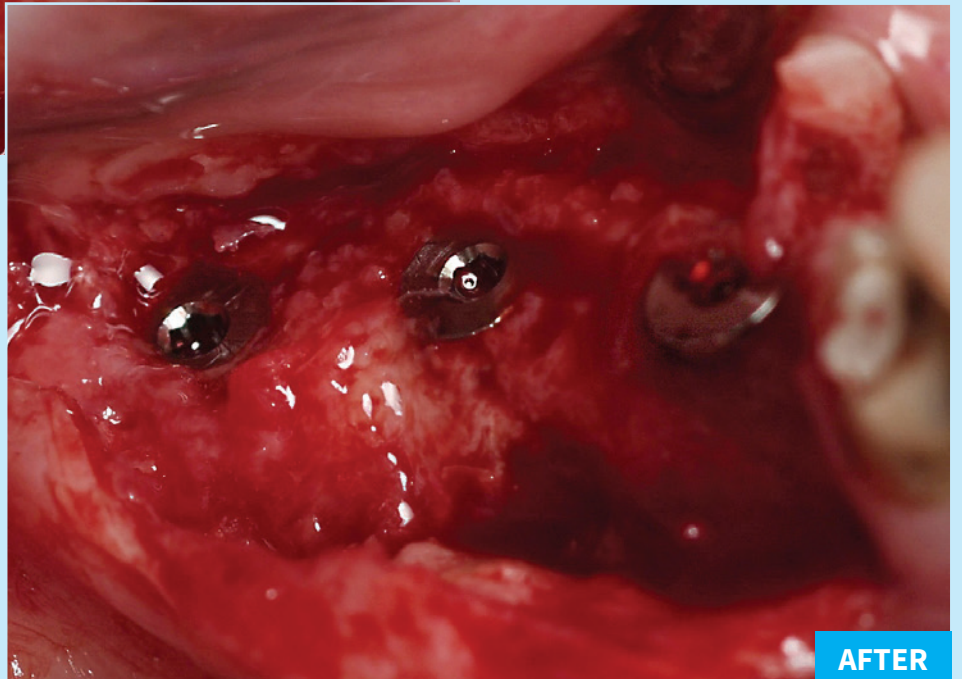
New bone formation with DSI SpongeGraft



BEFORE



Time period
= 12 weeks



AFTER