# Cardiac Computed Tomography to exclude left atrial appendage thrombus in atrial arrhythmias prior to electrical cardioversion during the COVID-19 pandemic

Jeffrey Sebastian, Tina Thomas, Francis Wu, Su Yin Tang, Budresh Joshi, Niels van Pelt, Ruvin Gabriel, Tim Sutton, Mansi Turaga, Jen-Li Looi

Atrial fibrillation (AF) and atrial flutter (AFL) are common causes of hospitalisation. Restoring sinus rhythm with cardioversion is performed in patients with AF/AFL in an effort to improve cardiac function and relieve symptoms.[1] Our group had recently showed that an early rhythm control strategy, with either early inpatient transoesophageal echocardiogram (TOE)-guided direct current cardioversion (DCCV) or ablation in patients hospitalised with AF or AFL and decompensated heart failure with reduced ejection fraction, had a low rate of all-cause mortality and rehospitalisation for heart failure at one year.[2]

TOE has an important role in guiding DCCV in AF patients of unknown or prolonged duration, and without the need for prolonged anticoagulation before the procedure.[3] Currently, TOE is considered the gold standard imaging modality to evaluate left atrial appendage (LAA) anatomy and morphology prior to DCCV.[4] COVID-19 poses a unique set of challenges to the healthcare system due to its rapid spread, intensive resource utilisation and relatively high morbidity and mortality. TOE is considered a high-risk procedure for possible aerosol transmission of this infection. Therefore, the American Society of Echocardiography recommends avoiding TOE and the use of alternative diagnostic tools for LAA imaging whenever possible.[5] Cardiac computed tomography (CCT) has been proposed as an alternative imaging method to exclude LAA thrombus prior to DCCV. On CCT, the LAA is qualitatively evaluated in multiple axial planes for a filling defect, which is defined as incomplete visualisation or opacification of the entire LAA with iodine contrast on a first pass or a delayed scan (Figure 1).

This study describes our experience of utilising CCT as an alternative imaging modality to exclude LAA thrombus prior to DCCV in patients with atrial arrhythmias at Middlemore Hospital from 1 January 2021 until 1 January 2022. Patients with atrial arrhythmia requiring DCCV who underwent CCT were identified from the All New Zealand Acute Coronary Syndrome Quality Improvement (ANZACS-QI) cardiac CT registry.

The demographic characteristics of patients who underwent CCT are summarised in Table 1. A total of 97 patients (71.1% men, mean age 58.2±14 years) underwent CCT as inpatients during the study period. All but one CCT scans were of diagnostic quality. More than 40% were European, 23.7% were Māori, 21.6% were Pasifika and 5.2% were Asian. The mean body mass index (BMI) of the study population was 33.8±8.4kg/m$^2$, and more than 60% of the study population had a BMI of ≥30kg/m$^2$.

More than 50% of patients were in AF. All patients underwent echocardiography prior to CCT. Two-thirds of patients had a significant reduction in left ventricular systolic (LV) on echocardiography during CCT: 8.2% had mild/mild–moderate LV impairment, and 59.8% had moderate/moderate–severe/severe LV impairment. 10 patients (10.3%) had slow flow/probable thrombus in the left atrium (LA) or LAA on CCT and four patients (4.1%) had definite thrombus. 83 patients underwent DCCV directly after CCT and none had periprocedural stroke. Six patients self-reverted to sinus rhythm and one patient underwent acute AFL ablation. One patient had an incidental finding of pulmonary embolus, and therefore did not undergo DCCV. Of the 10 patients with slow flow/probable LA/LAA thrombus on CCT, one patient self-reverted to sinus rhythm and the others were considered to have slow flow in LA/LAA and underwent DCCV without compli-

cation. Two out of the four patients with definite thrombus on CCT underwent TOE, which confirmed LAA thrombus. One patient had a repeat TOE after a month of adequate anticoagulation, which showed resolution of LAA thrombus, and one patient had a repeat CCT that showed no thrombus.

CCT is a well-established technique for the evaluation of left atrial and pulmonary vein anatomy prior to radiofrequency catheter ablation of AF.[6,7] In addition, CCT has been utilised as a non-invasive imaging modality for the detection of LAA thrombus before AF ablation for reducing the risk of periprocedural thromboembolic events.[8] Two recent meta-analyses[9,10] demonstrate that CCT plays an important role in excluding LA/LAA thrombus before AF ablation and in the evaluation of patients with suspected cardioembolic cerebrovascular accidents with a high sensitivity and specificity, however, there is a paucity of data on its role prior to DCCV.

The COVID-19 pandemic has forced us to reconsider how best to limit cardiac imaging procedures that generate aerosols in order to minimise the risk of cross-infection for both imagers and patients. Our study shows that for patients with acute atrial arrhythmia requiring DCCV, CCT is a safe and useful alternative to TOE.

TOE often requires intravenous sedation with benzodiazepine (e.g., midazolam) alone or in combination with intravenous narcotic (e.g., fentanyl). Benzodiazepines can depress respiratory and haemodynamic function, particularly in patients with impaired LV function, in elderly patients and in obese patients who frequently have difficult airways to manage and are at risk of respiratory complications.[11] Sedation is not required during CCT and would be a safer imaging tool for these patients. In our study, with a large proportion of patients with significant LV systolic impairment and an elevated BMI, diagnostic CCT was safely performed with most not requiring additional testing with TOE.

Iodine contrast agents used during CCT can cause contrast-induced nephropathy in patients with CKD with estimated glomerular filtration rates <30mL/min/1.73m2. Thus, TOE may be the preferred option to assess the LAA in these patients.

Although limited by a small number of patients, our study provides our real-world experience of utilising CCT to exclude LAA thrombus prior to DCCV in acute atrial arrhythmias. Importantly, CCT appears safe and effective to exclude LAA thrombus prior to DCCV.

**Table 1:** Clinical characteristic of patients who underwent cardiac computed tomography prior to direct current cardioversion.

| | **Total (n=97)** |
|---|---|
| **Gender** | |
| Male | 69 (71.1%) |
| Female | 28 (28.9%) |
| Age (years), (mean+SD) | 58.2+14 |
| **Ethnicity** | |
| NZ European | 46 (47.4%) |
| Māori | 23 (23.7%) |
| Pacific peoples | 21 (21.6%) |
| Asian | 5 (5.2%) |
| Middle Eastern/Latin American/African | 2 (2.1%) |
| **BMI (n, %)** | |
| <25 | 12 (12.4%) |
| 25–29 | 18 (18.6%) |
| >30 | 67 (69.1%) |

**Table 1 (continued):** Clinical characteristic of patients who underwent cardiac computed tomography prior to direct current cardioversion.

| | |
|---|---|
| Weight (kg), (mean+SD) | 101.7+27 |
| BMI (kg/m2), (mean+SD) | 33.8+8.4 |
| **Rhythm during CT** | |
| Atrial fibrillation | 57 (58.8%) |
| Atrial flutter | 40 (41.2%) |
| **LV function during CT** | |
| Normal/Low normal | 31 (27.5%) |
| Mild/Mild-moderate | 8 (8.2%) |
| Moderate/Moderate-severe/Severe | 58 (59.8%) |
| Slow flow or probable thrombus in LA/LAA | 10 (10.3%) |
| Definite LAA thrombus | 4 (4.1%) |

Abbreviations: BMI – body mass index; BSA – body surface area; CT – computed tomography; LV – left ventricular; LA – left atrium; LAA – left atrial appendage.

**Figure 1: a)** CCT view of the left atrial appendage. There is complete opacification of the left atrial appendage with contrast, indicating no evidence of thrombus and; **b)** a thrombus (arrow) is seen in the left atrial appendage.

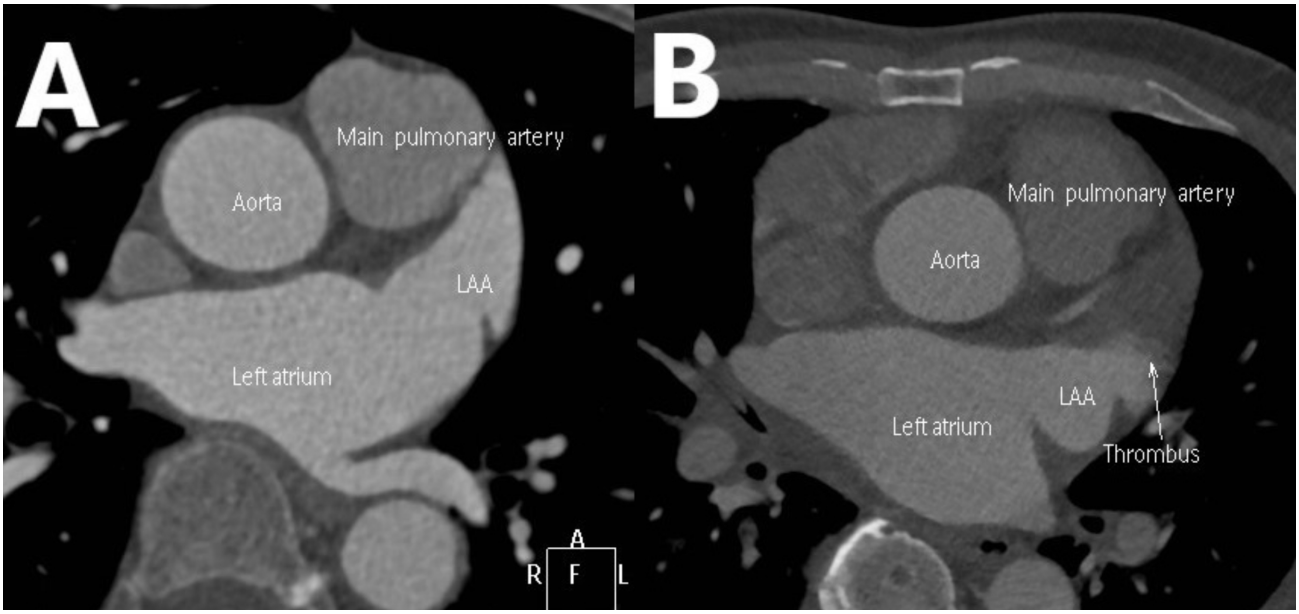

**COMPETING INTERESTS**

Nil.

**AUTHOR INFORMATION**

Jeffrey Sebastian: Department of Cardiology, Middlemore Hospital, Private Bag 93311, Ōtāhuhu, Auckland, New Zealand.

Tina Thomas: Department of Cardiology, Middlemore Hospital, Private Bag 93311, Ōtāhuhu, Auckland, New Zealand.

Francis Wu: Department of Radiology, Middlemore Hospital, Private Bag 93311, Ōtāhuhu, Auckland, New Zealand

Su Yin Tang: Department of Radiology, Middlemore Hospital, Private Bag 93311, Ōtāhuhu, Auckland, New Zealand.

Budresh Joshi: Department of Radiology, Middlemore Hospital, Private Bag 93311, Ōtāhuhu, Auckland, New Zealand.

Niels van Pelt: Green Lane Cardiovascular Service, Auckland City Hospital, 2 Park Road, Grafton, Auckland 1023, New Zealand.

Ruvin Gabriel: Department of Cardiology, Middlemore Hospital, Private Bag 93311, Ōtāhuhu, Auckland, New Zealand.

Tim Sutton: Department of Cardiology, Middlemore Hospital, Private Bag 93311, Ōtāhuhu, Auckland, New Zealand.

Mansi Turaga: Department of Cardiology, Middlemore Hospital, Private Bag 93311, Ōtāhuhu, Auckland, New Zealand.

Jen-Li Looi: Department of Cardiology, Middlemore Hospital, Private Bag 93311, Ōtāhuhu, Auckland, New Zealand.

**CORRESPONDING AUTHOR**

Jen-Li Looi: Department of Cardiology, Middlemore Hospital, Private Bag 93311, Ōtāhuhu, Auckland, New Zealand. Ph: +649 2760061; Fax: +649 2709746. E: JenLi.Looi@middlemore.co.nz

**REFERENCES**

1. Pritchett EL. Management of atrial fibrillation. N Engl J Med. 1992;326(19):1264-71.
2. Foo FS, Kerr A, Gabriel R, Heaven D, Looi JL, Lund M, et al. Early direct current cardioversion or ablation for atrial fibrillation or atrial flutter and acute decompensated heart failure. N Z Med J. 2019;132(1496):39-46.
3. Klein AL, Murray RD, Grimm RA. Role of transesophageal echocardiography-guided cardioversion of patients with atrial fibrillation. J Am Coll Cardiol. 2001;37(3):691-704.
4. Puchalski MD, Lui GK, Miller-Hance WC, Brook MM, Young LT, Bhat A, et al. Guidelines for Performing a Comprehensive Transesophageal Echocardiographic: Examination in Children and All Patients with Congenital Heart Disease: Recommendations from the American Society of Echocardiography. J Am Soc Echocardiogr. 2019;32(2):173-215.
5. Nicoara A, Maldonado Y, Kort S, Swaminathan M, Mackensen GB. Specific Considerations for the Protection of Patients and Echocardiography Service Providers When Performing Perioperative or Periprocedural Transesophageal Echocardiography during the 2019 Novel Coronavirus Outbreak: Council on Perioperative Echocardiography Supplement to the Statement of the American Society of Echocardiography Endorsed by the Society of Cardiovascular Anesthesiologists. J Am Soc Echocardiogr. 2020;33(6):666-9.
6. Lacomis JM, Wigginton W, Fuhrman C, Schwartzman D, Armfield DR, Pealer KM. Multi-detector row CT of the left atrium and pulmonary veins before radio-frequency catheter ablation for atrial fibrillation. Radiographics. 2003;23 Spec No:S35-48; discussion S-50.
7. Jongbloed MR, Dirksen MS, Bax JJ, Boersma E, Geleijns K, Lamb HJ, et al. Atrial fibrillation: multi-detector row CT of pulmonary vein anatomy prior to radiofrequency catheter ablation--initial experience. Radiology. 2005;234(3):702-9.
8. Bhagirath P, van der Graaf AW, Karim R, van Driel VJ, Ramanna H, Rhode KS, et al. Multimodality imaging for patient evaluation and guidance of catheter ablation for atrial fibrillation - current status and future perspective. Int J Cardiol. 2014;175(3):400-8.
9. Yu S, Zhang H, Li H. Cardiac Computed Tomography Versus Transesophageal Echocardiography for the Detection of Left Atrial Appendage Thrombus: A Systemic Review and Meta-Analysis. J Am Heart Assoc. 2021;10(23):e022505.
10. Romero J, Husain SA, Kelesidis I, Sanz J, Medina HM, Garcia MJ. Detection of left atrial appendage thrombus by cardiac computed tomography in patients with atrial fibrillation: a meta-analysis. Circ Cardiovasc Imaging. 2013;6(2):185-94.
11. Hilberath JN, Oakes DA, Shernan SK, Bulwer BE, D'Ambra MN, Eltzschig HK. Safety of transesophageal echocardiography. J Am Soc Echocardiogr. 2010;23(11):1115-27; quiz 220-1.