Challenges in the treatment of a stingray injury: a rare case report in a rural New Zealand hospital

Benjamin J L Black, Monica J Londahl, Konrad K Richter

Though stingrays are commonly found in the vast Australasian waters, severe injuries are rare. Ray venom remains a poorly understood phenomenon, and the treatment of barb injuries can be challenging due to envenomation obscuring the clinical picture, as well as delayed presentations with bacterial infections.[1,2] There is a concern in New Zealand and other temperate climates that as climate change progresses, these injuries will become more common, as stingrays become a more familiar resident in our beaches.[3] Knowledge of the management of these injuries is therefore a useful addition to the armamentarium of frontline emergency and trauma staff. Here, we report a rare case of a thoracic penetrating stingray injury that required emergency treatment in our rural hospital.

Case presentation

A 48-year-old man was walking towards the shore at Ōreti Beach, near Invercargill in New Zealand, in water approximately 30cm deep, when he suffered severe pain in the right foot followed suddenly by a stab wound to the left chest.

There was a significant disturbance in the water to the right of him, and a large marine creature briefly surfaced which he caught a glimpse of. He managed to get out of the water unassisted, and an ambulance was called. The patient presented to our rural hospital with severe global chest pain, diaphoresis, dyspnoea and hypoxia (oxygen saturation of 90% while on 15L of oxygen via Hudson mask). He had a 4cm wound in the left chest with subcutaneous tissue visible (Figure 1); this was in the seventh intercostal space in the midaxillary line. He also had a 5mm puncture site on the plantar aspect of the right foot just proximal to the fifth digit (Figure 2). On chest examination, he had bilateral air entry with no clear lateralising signs. A small pneumothorax was suggested on chest X-ray (Figure 3), and an urgent intercostal drain was placed based on severe symptoms with no large release of air and no significant improvement to his oxygenation.

He was further investigated with extended Focused Assessment with Sonography in Trauma (e-FAST), which showed no free fluid in the abdomen, chest or pericardium. A CT scan of the chest (Figure 4) and abdomen was also performed which showed a small residual pneumothorax with no other significant injury seen in the chest or abdomen.

Treatment

The patient was treated with liberal IV opioids during his early presentation to ED; he received 250mcg of fentanyl, 8mg of morphine as well as 60mg of ketamine with little effect on his pain. His chest wound was explored in the emergency room with no obvious intrusion into the thoracic cavity found. After a washout and exploration of the wound with no debris found, the incision was primarily closed with non-absorbable sutures. The wound on his foot was inspected, washed out and left open. Local anesthesia, by way of infiltration during the exploration of the wound, as well as regional anesthesia (posterior tibial nerve block) was much more effective in improving his pain, significantly reducing his opioid requirement. Broad-spectrum IV antibiotics were used as well as a tetanus ADT™ booster. His pain was markedly improved the next day, and the intercostal drain was removed.

Outcome and follow-up

The patient made a good recovery from his injuries and was discharged from hospital after a two-night admission. He remained well six months following the injury with no major delayed complication becoming evident.

2022 Jul 15; 135(1558). ISSN 1175-8716
www.nzma.org.nz/journal

Figure 1: Stingray injury chest.

Figure 2: Stingray injury to the foot with oedema and erythema.

Figure 3: Stingray injury X-ray chest with pneumothorax.

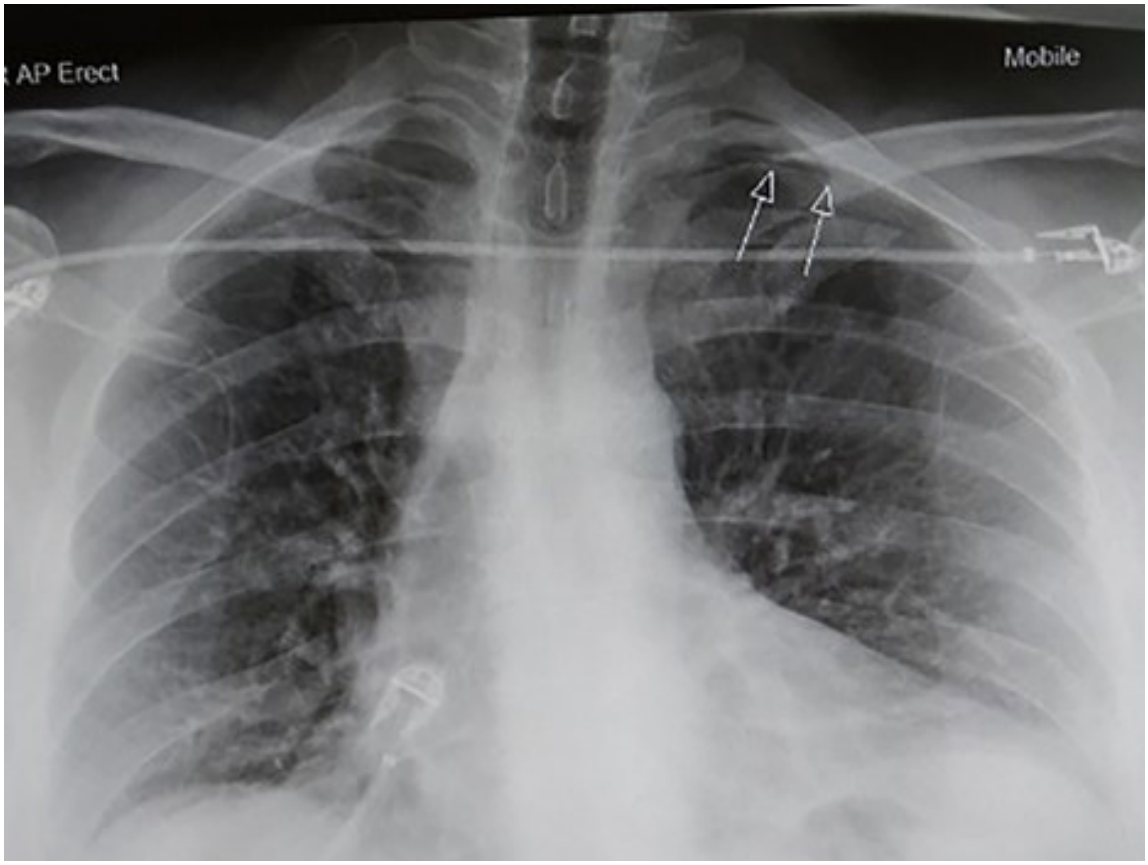

Figure 4: Chest CT with injury site.

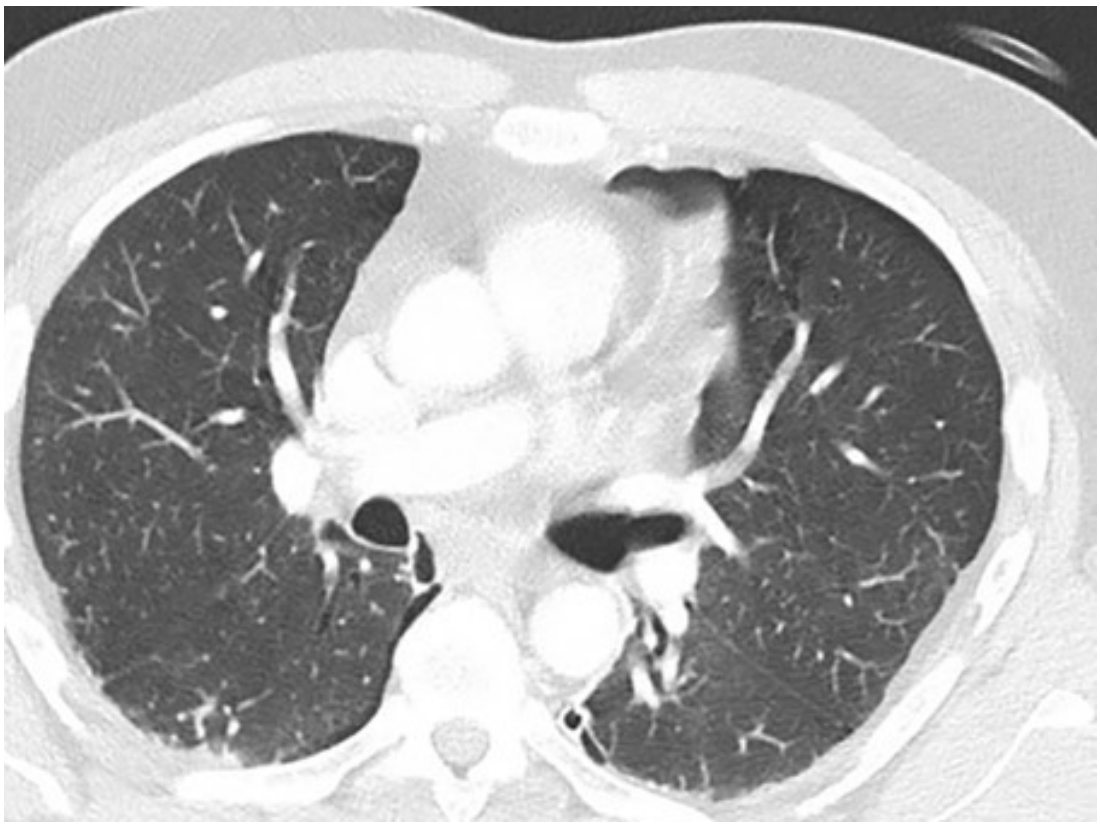

Discussion

The pertinent factor, in this case, was that the patient's clinical signs were inconsistent with the underlying traumatic pathology. His presentation appeared to represent a more severe injury than what was discovered. The injury, instead, represented significant local and systemic envenomation from a stingray barb. Local anesthesia was the most effective in terms of analgesia for this patient, and indeed, this is in keeping with previously reported cases.[4] There is no anti-venom for stingray toxin, and management is primarily supportive care.[4] Systemic envenomation has a varied presentation, but commonly described symptoms include diaphoresis, syncope, nausea, diarrhea, and hypotension.[1,4] There have also been cases reported of cardiac arrhythmias following stingray envenomation, including supraventricular bigeminy.[5]

The mainstay of management of stingray penetrating trauma remains early explorative debridement, tetanus prophylaxis, and broad-spectrum antibiotics, which is common to most dirty penetrating wounds. Stingray toxin itself has been known to cause necrosis, and the injuries have been associated with necrotizing fasciitis and osteomyelitis, especially if they have sub-optimal initial wound management.[6] There have been previous necrotising soft tissue infections reported following stingray injuries involving vibrio subspecies similar to other marine organism related injuries.[5] Fluoroquinolones are often added to empiric antibiotic regimes to cover for this possibility.

Stingray venom is heat labile and can be denatured with hot water immersion of the affected areas.[1,2,4] The appropriate application of hot water would have been impractical for a penetrating thoracic wound like the one described, but it can be beneficial for more superficial wounds if the patient can tolerate this. Care must be taken to avoid thermal burns if using this technique; the toxin has to be exposed to temperatures of 45–50°C to denature, which will be intolerable to some patients. It is also an important consideration that a patient in such circumstances will typically be too distressed to accurately gauge the water's temperature, therefore ensuring someone other than the patient assesses the water temperature is necessary.

Although there is no randomised data, prospective studies indicate that this is an effective treatment for pain in many circumstances.[7] It also has been previously hypothesised that local anesthetic itself may have some direct counteraction to stingray toxin.[2]

There are only a handful of severe thoracic injuries from stingrays reported in Australasia, of which even fewer resulted in fatalities, with the most notable being Steve Irwin. The fatalities involved cases of direct mortal injuries from

Figure 5: Accident Compensation Data for New Zealand: 2008 to 2018.

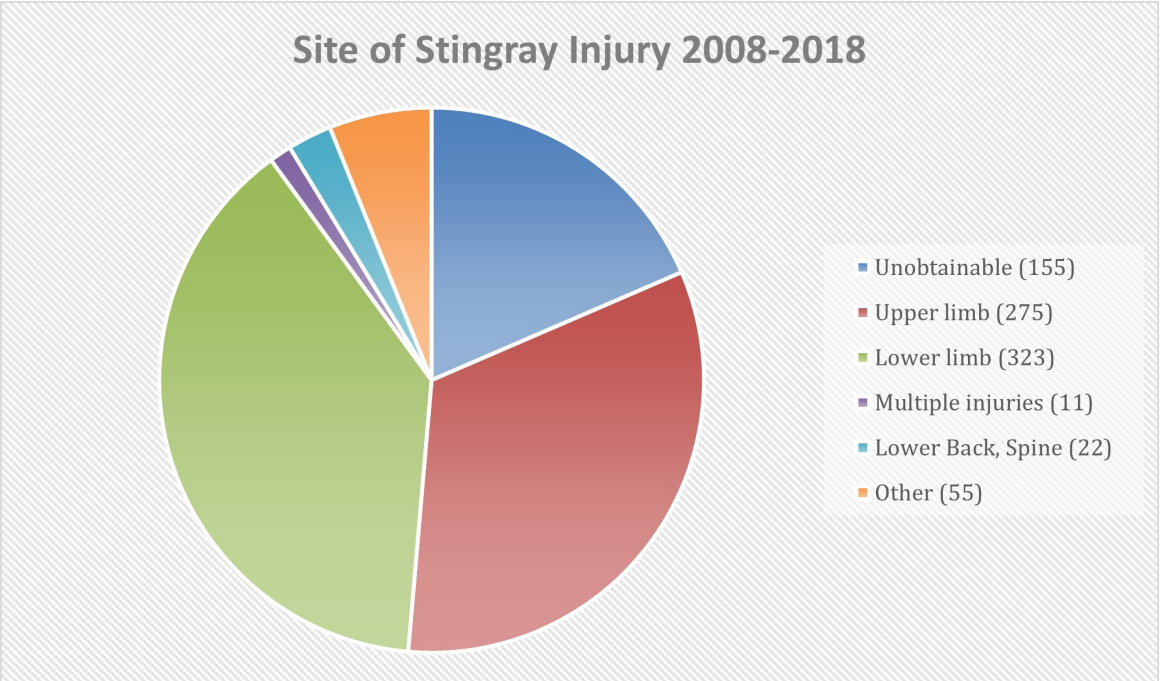

trauma and delayed presentations secondary to necrosis and infection.[1,2] Traumatic pneumothoraxes are rare, but have been previously reported secondary to stingray injuries.[8] Most injuries from stingrays are to the upper and lower extremity when unlucky ocean goers encounter them when they are close to shore. This is confirmed by our national accident compensation data which shows 89% of the injuries with complete data related to stingrays in the last decade have been from extremity trauma (Figure 5). Usually docile creatures, stingrays tend to attack only if felt to be threatened.[4]

This case represents another addition to the literature of a severe penetrating thoracic trauma created by a stingray barb, and also another description of the significant regional and systemic effects of stingray toxin. The standard of care remains supportive care, generous local anesthesia, exploration, and debridement of a wound, which could include heated irrigation fluid as well as broad-spectrum antibiotics.

COMPETING INTERESTS

Nil.

AUTHOR INFORMATION

Benjamin J L Black MBChB: Surgical Registrar, Department of Surgery, Southland Hospital, Invercargill, New Zealand.

Monica J Londahl MPH: Research Fellow, University of Otago, School of Medicine, New Zealand.

Konrad K Richter MD, PHD: Consultant Surgeon, University of Otago, School of Medicine, New Zealand.

CORRESPONDING AUTHOR

Associate Professor Konrad Klaus Richter: Consultant General Surgeon, Surgical Oncologist, Colorectal Surgeon; Clinical Associate Professor Dunedin School of Medicine, Department of Surgery, Southland Hospital, Kew Road, Invercargill, New Zealand. 03 218 1949. konradklaus.richter@gmail.com

URL

www.nzma.org.nz/journal-articles/challenges-in-the-treatment-of-a-stingray-injury-a-rare-case-report-in-a-rural-new-zealand-hospital

REFERENCES

1. Evans R, Davies R. Stingray injury. Emerg Med J. 1996;13(3):224-225.
2. Fenner P, Williamson J, Skinner R. Fatal and non-fatal stingray envenomation. Med J Aust. 1989;151(11-12):621-625.
3. Needleman R, Neylan I, Erickson T. Environmental and Ecological Effects of Climate Change on Venomous Marine and Amphibious Species in the Wilderness. Wilderness Environ Med. 2018;29(3):343-356.
4. Slaughter R, Beasley D, Lambie B, Schep L. New Zealand's venomous creatures. N Z Med J. 2009;122:83-97.
5. Ikeda T. Supraventricular bigeminy following a stingray envenomation: a case report. Hawaii Med J. 1989;48(5):162-164
6. Ho PL, Tang W-M, Yuen K-S. Necrotizing fasciitis due to Vibrio alginolyticus Following an Injury Inflicted by a Stingray. Scand J Infect Dis. 1998;30(2):192-193.
7. Myatt T, Nguyen B J, Clark R F, et al. A prospective study of stingray injury and envenomation outcomes. J Emerg Med. 2018 Aug 1;55(2):213-7.
8. Suzuki T, Takada T, Fudoji J. Traumatic Pneumothorax Associated With Penetrating Neck Injury Caused by a Stingray: A Case Report. Wilderness Environ Med. 2017 Jun;28(2):119-121

