THE NEW ZEALAND MEDICAL JOURNAL
Journal of the New Zealand Medical Association

Using real-time ultrasound to teach living anatomy: an alternative model for large classes

Mark D Stringer, Lynda J Duncan, Latika Samalia

Abstract

Aims Ultrasound is a safe, non-invasive and versatile imaging modality used widely in clinical practice. Several studies have reported using ultrasound imaging to supplement teaching of clinical anatomy to medical students but most have attempted to teach basic ultrasound skills in addition to normal sonographic anatomy. These small group teaching sessions are labour intensive and need appropriate resourcing of equipment and personnel. We report experience of an alternative approach suitable for large classes with more limited resources.

Methods A single 1-hour ultrasound demonstration of 'living anatomy' of the abdomen, pelvis and neck was conducted using a young female model as the subject. Scans were performed by an experienced sonographer with images projected on to a large lecture theatre screen; medical student interaction was encouraged by two clinical anatomists.

Results Anonymous evaluation of 152 returned questionnaires (≥ 63% response rate) showed that more than 80% of respondents considered the session had stimulated and improved their understanding of anatomy.

Conclusions Whilst this method of teaching anatomy using ultrasound does not offer hands-on experience, it does provide students with an introduction to the clinical utility of ultrasound and, by focusing on anatomic findings rather than the acquisition of technical imaging skills, reinforces the learning of clinical anatomy.

Several studies have reported on the use of ultrasound to teach anatomy to medical students.[1–9] Three of these were published as abstracts only,[4–6] three focused on echocardiography,[3,7,9] and all except two[7,9] attempted to teach students to acquire basic sonographic imaging skills as well as anatomy.

Although the vast majority of students in all studies evaluated ultrasound as a useful learning tool for reinforcing anatomy and enjoyed the practical hands-on experience, some limitations were noted including large group size restricting access to equipment[1,2] and the limited availability of places (less than 20% of the class cohort in two studies).[4,7]

Using ultrasound to reinforce anatomy appears to be educationally worthwhile but equipping medical students with basic ultrasound skills to achieve this, whilst a laudable goal, has some drawbacks. It is labour and resource intensive requiring time, appropriate numbers of trained supervisors, and sufficient equipment to teach small groups. There is also the potential danger of sending the wrong message: ultrasound imaging is highly operator dependent and it often takes months or even longer to become proficient. It is arguable just how much "...students acquire the skills to

perform and interpret ultrasound..." in short sessions where they are also focusing on learning normal anatomy.[6] This concern also has an ethical dimension since it is possible that a student who volunteers to be examined might be prompted to do so because of a personal health concern and be falsely reassured by a "normal scan". Unless ultrasound imaging is vertically integrated into the curriculum allowing students enough time and exposure to develop their skills [10] it is unlikely that these obstacles will be overcome.

Ivanusic et al (2010) reported using an alternative approach consisting of a 1-hour echocardiography demonstration performed by an expert examining a student volunteer with images projected to the remainder of the student group.[7] This was highly rated by the students who commented that it reinforced lecture material in a stimulating way and demonstrated clinically relevant anatomy. Recently, Griksaitis et al (2012) reported a similar but shorter (30 minute) class demonstration to teach cardiac anatomy; they took the precaution of screening the student volunteer prior to the demonstration.[9]

As in many other institutions, we use modern imaging techniques (computed tomography [CT], magnetic resonance imaging [MRI], endoscopy videos etc) to supplement and reinforce the teaching of clinical anatomy. In 2008, we introduced a single ultrasound demonstration session to third year medical students. The popularity of this session encouraged us to retain it and this report describes our experience to date.

Methods

A single 1-hour ultrasound demonstration of living anatomy was delivered to third year medical students (class size = 240–260) in 2008, 2009, and 2011 (in 2010 an abdominal body painting session was trialled in its place). In 2008, attendance was entirely voluntary but, after positive student feedback, the demonstration became a scheduled class activity.

The session was timed to coincide with the end of a regional and clinical anatomy module which is in the latter part of the academic year and precedes the students moving to ward-based learning in years 4 and 5 of the curriculum. An experienced medical sonographer (LD) gives a brief introduction on the properties of transmitted sound waves, image orientation, the safety of ultrasound and its advantages, limitations, and clinical applications.

The sonographer then demonstrates selected anatomy in the abdomen, pelvis, and neck in a consenting young, slim, female volunteer (a paid actress). The actress is scanned in the week prior to the demonstration in order to exclude pathology and to ensure that she is comfortable with the scanning process. She is instructed to attend the demonstration with a full bladder and having fasted overnight (the demonstration is held at 9 am). Sonographic images are projected on to a large lecture theatre screen (Figure 1). Two clinical anatomists (MDS and LS) provide commentary and encourage interactive questioning from the student audience.

High resolution ultrasound images are obtained using an ACUSON Antares™ Premium Edition machine (Siemens Medical Solutions, CA, USA) equipped with a CH2-6 curvilinear transducer (2.86–3.33 MHz) for abdominal imaging and a VF13-5 linear transducer (10 MHz) for scanning the neck and anterior abdominal wall. The scanning sequence begins with the pelvis, after which the model takes a break to empty her bladder, and then scanning continues with the abdomen and neck. Table 1 lists the structures that are demonstrated. Colour Doppler is used to show blood/fluid flow (Figure 2) and typical arterial and venous waveforms.

Figure 1. Organisation of the ultrasound demonstration session. Sonographic images are projected on to a large lecture theatre screen (lighting is reduced to enhance viewing).

Table 1. Anatomical structures demonstrated by ultrasound

Region	Structures demonstrated
Pelvis	- uterus (including the endometrium and phase of the menstrual cycle) and cervix - ovaries (with follicles) - rectouterine pouch - bladder (including ureteric peristalsis and urine flow into the bladder) - external iliac and femoral vessels (emphasising the surface marking of the latter)
Abdomen	- rectus abdominis muscle and rectus sheath with epigastric vessels (the inferior epigastric artery being traced from its origin from the external iliac artery near the deep inguinal ring) - liver (right and left lobes, portal vein, hepatic artery and veins) and diaphragm - gallbladder and extrahepatic bile ducts - spleen - kidneys (including measurement of length) - pancreas - abdominal aorta (including origin of the celiac trunk and superior mesenteric arteries) and inferior vena cava - renal vessels - gut peristalsis (and the difficulties of imaging the normal appendix)
Neck	- carotid sheath - thyroid gland

Figure 2. An example of 'living anatomy'. A transverse section of the bladder with a peristaltic jet of urine shown by colour Doppler

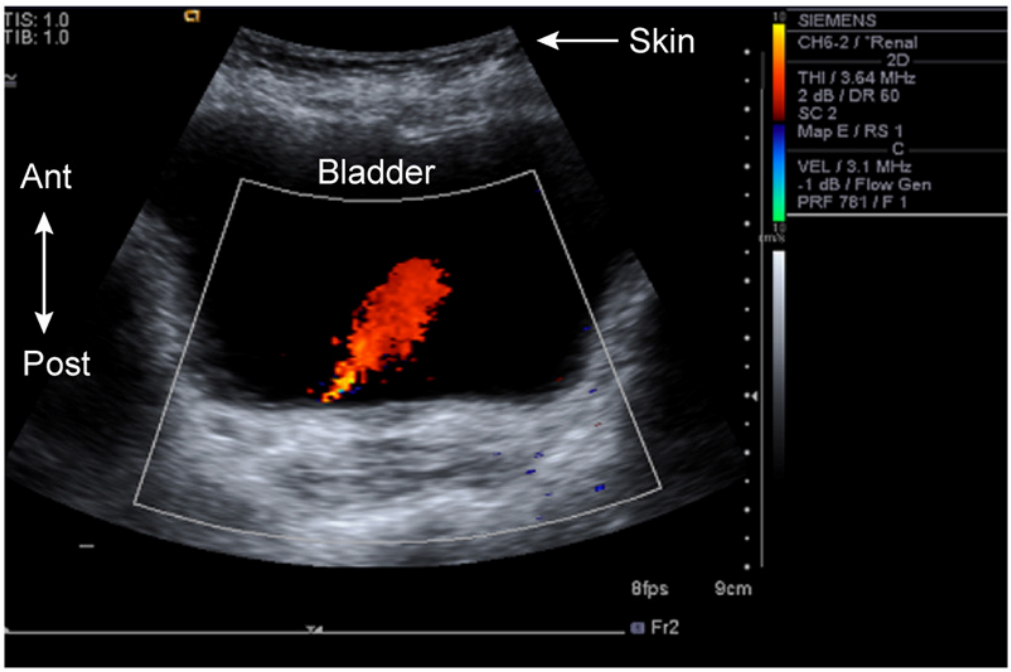

At the end of the first ultrasound demonstration in 2008, students were invited to complete an anonymous questionnaire evaluating the session using a five-point Likert scale to grade responses, with responses ranging from grade 1 (excellent) to grade 5 (very poor). Questionnaires were collected by a student representative and analysed independently by the University of Otago Higher Education Development Centre.

Results

152 questionnaires were returned, a response rate of at least 63% (attendance in 2008 was voluntary and the maximum possible class size was 240). Ratings are summarised in Table 2. Overall, responses were extremely favourable, with more than 90% of respondents considering that the session had stimulated and improved their understanding of anatomy.

Free text comments were overwhelmingly positive and included statements such as "a good introduction to using ultrasound", "good to have combination of different backgrounds of demonstrators", "awesome to see organs in the living body", "puts anatomy in context", and "good to get the exposure to a clinical technique we haven't seen much of yet". There were a few negative comments such as "everything looks like shades of grey", "the class size was too big to encourage questions", and "I couldn't see where the probe was on the subject".

Finally, a few students commented that they would like to see the heart, a pregnant patient, or a male subject. As a measure of the success of the session, third year medical students voted it the best teaching innovation for 2008.

Table 2. Summary of student responses to the evaluation questionnaire (n = 152)

Questions	Grade 1 & 2 (very positive and positive)	Grade 3 (neutral)	Grade 4 & 5 (negative)
1. Overall, how valuable was this session for you?	95%	4%	1%
2. Did this session stimulate your interest in anatomy?	91%	7%	3%
3. Did the session improve your understanding of abdominal/pelvic anatomy?	82%	14%	4%
4. Did you like the interactive style of presentation?	94%	5%	1%
5. Was the session well organised?	95%	4%	0%
6. Do you think this approach is useful as an aid to learning the clinical relevance of anatomy?	97%	2%	1%
7. Would you like to see this session repeated within future Regional & Clinical Anatomy modules?	98%	1%	1%
8. What did you like best about the session?	Free text responses (see text)		
9. What did you like least about the session?			
10. Any other comments			

Discussion

Using ultrasound imaging to supplement other methods of teaching anatomy offers several opportunities. Firstly, it allows anatomy to be visualised in real time enabling students to appreciate dynamic aspects such as blood flow, peristalsis, and how anatomy may be influenced by respiration, posture, and body fat. Secondly, it underlines the clinical application of anatomical knowledge, particularly when structures are demonstrated by an expert who is using the same technique in everyday clinical practice. Thirdly, it complements standard anatomy teaching by emphasising clinical aspects such as renal length which often receive little attention when learning anatomy. Finally, it may help to emphasise the importance of human anatomical variation. [8]

We deliberately introduced this session after students had completed the bulk of their anatomy learning in anticipation of them integrating the clinical real-time sonographic imaging with their existing knowledge gained from dissection, prosections, models, body painting, radiography, and cross-sectional imaging (CT and MRI). We were not aiming to teach students how to perform an ultrasound scan. Instead, we wanted to introduce them to this safe, non-invasive and widely available imaging technique with its unique strengths and weaknesses and enhance their learning of anatomy in the process.

Previous studies reporting the use of ultrasound to teach anatomy to medical students are shown in Table 3,[1–9] which summarises the structure of each course, study subjects and anatomical regions studied. We chose a class demonstration with a hired model for a variety of reasons. Logistically, we had neither the resources nor manpower to offer hands-on training.

A high-quality ultrasound machine equipped with a range of transducers was used to provide images of optimum resolution, rather than relying on potentially inferior images displayed by smaller portable machines used in other studies.[3,7,11,12] It is well known that the yield from ultrasound is highly operator dependent. Therefore, demonstration by a skilled expert should be more rewarding and using an actor/actress also removes any ethical dilemmas or anxiety surrounding the use of student volunteers (both the potential to discover pathology and that of providing false reassurance from a 'normal scan' done by a novice).

Although the students rated the session highly, sonographic visualisation of anatomy in this way does have limitations. The orientation of the image can be difficult to conceptualise when moving between structures and regions and students are denied hands-on experience.

We only evaluated learning by asking the students to what extent the session had improved their understanding of anatomy. Consequently, we addressed Kirkpatrick's first level of effectiveness (reaction) but did not attempt to quantify the learning opportunity or its impact on the application of anatomy (behaviour and results).[13] The positive wording of our questionnaire may have introduced a bias toward favourable responses. We would agree with Ivanusic et al. (2010)[7] that ultrasound is best used to highlight specific anatomical features or concepts and used as an adjunct to other methods of teaching anatomy (including cross-sectional imaging), rather than as a substitute for these.

Interestingly, first year medical students in the UK randomised to learning gross cardiac anatomy by either cadaver prosections or a live echocardiography demonstration showed similar educational performance scores;[9] unfortunately, the authors did not investigate the educational utility of combining these approaches. Finally, our demonstration was restricted to the abdomen, pelvis, and neck but we are interested in extending this to include echocardiography as others have done.[3,7,9]

Ultrasound imaging has been reported in other educational contexts other than primarily as an adjunct to teaching anatomy to medical students. For example, Talarico (2010) [14] from Indiana made reference to ultrasound examination of cadavers during the delivery of a non-medical anatomy course and Zumwalt et al (2010)[15] at Boston University School of Medicine described how radiology residents spent about 20-30 minutes teaching senior medical students how to use an ultrasound machine during a radiology module. Other undergraduate medical programs have focused on ultrasound imaging in the emergency room,[16] in assisting physical examination of the heart,[17] liver,[18] abdomen,[11,19] or neck,[8] or simply to provide a primer in basic ultrasound technical skills.[20]

Table 3. Summary of previous studies reporting the use of ultrasound to teach anatomy

Author	Institution	Medical Students and Mode of delivery	Study subjects	Study region
Teichgräber et (1996)[1]	Hannover Medical School, Germany	First year Up to 10 students per US machine Introductory lecture + 2 or 6 hour seminar. Hands-on	Student peers	Abdomen and pelvis
Heilo et al (1997)[2]	University of Oslo Medical School, Norway	Second year Groups of 15 students (up to 8 per machine); 1-2 hours. Hands-on	Student peers	Abdominal viscera, thyroid, and forearm
Wittich et al (2002)[3]	Mayo Medical School, Minnesota, USA	First year Introduction (1.5 hour), small group training (1 hour), independent practice (mean 14 mins). Hands-on	Student peers	Cardiovascular
Wicke et al (2003)[4]	University of Vienna, Austria	Groups of 6-7 undergraduate students of variable seniority 10 weekly 3 hour sessions. Hands-on	Student peers	Abdomen and pelvis
Tshibwabwa and Groves (2005)[5]	McMaster University, Ontario, Canada	First year Groups of 6 students. 3 x 1.5 hour sessions. Hands-on	Not stated	Cardiovascular and renal
Tshibwabwa et al (2007)[6]	McMaster University, Ontario, Canada	Second year Groups of 6 students. Hands-on Duration of sessions not stated.	A normal "control model"	Upper and lower limbs (musculoskelet al)
Ivanusic et al (2010)[7]	University of Melbourne, Australia	Second year 1 hour demonstration by clinicians Images projected to class of 22 students	Student volunteers	Cardiovascular
Brown et al (2012)[8]	Universities of Arizona & Nebraska, USA	First year Class presentations (109 students) 3 x 20 min presentations	Not stated	Neck
Griksaitis et al (2012)[9]	Southampton & Durham Universities, UK	First year Class demonstration by clinician (53 students); 30 mins	Student volunteers	Cardiac

Rao et al (2008) evaluated first year medical students in Detroit who practiced assessing abdominal, cardiovascular, urinary, and musculoskeletal structures with a portable ultrasound machine during six 90-minute sessions; their goal was to provide a basic course in the application of clinical ultrasound which included normal sonographic anatomy.[12] While most students reported that the experience was positive there was a 39% fall off in attendance between the first and sixth sessions.

In conclusion, ultrasound is a safe and versatile imaging modality that can be incorporated into undergraduate medical curricula in a variety of ways but is effective at demonstrating real-time clinical anatomy. The logistic difficulties of educating large classes, the limited availability of skilled personnel and equipment, and time constraints can be overcome by using an ultrasound demonstration session.

Although this does not give students hands-on experience, it provides them with an introduction to the clinical utility of ultrasound and reinforces their anatomy learning rather than attempting to teach them basic ultrasound imaging skills. If, in the future, medical students in New Zealand are encouraged to acquire basic hands-on ultrasound imaging skills then this preliminary ultrasound demonstration delivered in the context of learning clinical anatomy could serve as a useful introduction.

Competing interests: None known.

Author information: Mark D Stringer[1]; Lynda J Duncan[2]; Latika Samalia[1]

1. Department of Anatomy, Otago School of Medical Sciences, University of Otago, Dunedin
2. Department of Radiology, Dunedin Hospital, Dunedin

Correspondence: Professor M D Stringer, Department of Anatomy, Otago School of Medical Sciences, University of Otago, PO Box 913, Dunedin, New Zealand. Fax: +64 (0)3 4797254; email: mark.stringer@anatomy.otago.ac.nz

Acknowledgements: We thank Chris Smith for the photographs and the University of Otago Higher Education Development Centre for analysis of course questionnaires.

References:

1. Teichgräber UK, Meyer JM, Poulsen Nautrup C, von Rautenfeld DB. Ultrasound anatomy: a practical teaching system in human gross anatomy. Med Educ. 1996;30:296–8.
2. Heilo A, Hansen AB, Holck P, Laerum F. Ultrasound 'electronic vivisection' in the teaching of human anatomy for medical students. Eur J Ultrasound. 1997;5:203–7.
3. Wittich CM, Montgomery SC, Neben MA, et al. Teaching cardiovascular anatomy to medical students by using a handheld ultrasound device. JAMA 2002;288:1062–3.
4. Wicke W, Brugger PC, Firbas W. Teaching ultrasound of the abdomen and the pelvic organs in the medicine curriculum in Vienna. Med Educ. 2005;37:476.
5. Tshibwabwa ET, Groves HM. Integration of ultrasound in the education programme in anatomy. Med Educ. 2005;39:1148.
6. Tshibwabwa ET, Groves HM, Levine MA. Teaching musculoskeletal ultrasound in the undergraduate medical curriculum. Med Educ. 2007;41:517–8.
7. Ivanusic J, Cowie B, Barrington M. Undergraduate student perceptions of the use of ultrasonography in the study of "living anatomy". Anat Sci Educ. 2010;3:318–22.
8. Brown B, Adhikari S, Marx J, Lander L, Todd GL. Introduction of ultrasound into gross anatomy curriculum: perceptions of medical students. J Emerg Med. 2012 [Epub ahead of print].
9. Griksaitis MJ, Sawdon MA, Finn GM. Ultrasound and cadaveric prosections as methods for teaching cardiac anatomy: a comparative study. Anat Sci Educ. 2012;5:20–6.
10. Hoppmann RA, Rao VV, Poston MB, et al. An integrated ultrasound curriculum (iUSC) for medical students: 4-year experience. Crit Ultrasound J. 2011;3:1–12.
11. Shapiro RS, Ko PK, Jacobson S. A pilot project to study the use of ultrasonography for teaching physical examination to medical students. Comput Biol Med. 2002;32:403–9.

12. Rao S, van Holsbeeck L, Musial JL, et al. A pilot study of comprehensive ultrasound education at the Wayne State University School of Medicine: a pioneer year review. J Ultrasound Med. 2008;27:745–9.
13. Kirkpatrick DL, Kirkpatrick JD. Transferring Learning to Behavior: Using the four levels to improve performance. San Francisco: Berrett-Koehler Publishers, 2005, p3–8.
14. Talarico EF Jr. A human dissection training program at Indiana University School of Medicine-Northwest. Anat Sci Educ. 2010;3:77–82.
15. Zumwalt AC, Lufler RS, Monteiro J, Shaffer K. Building the body: active learning laboratories that emphasize practical aspects of anatomy and integration with radiology. Anat Sci Educ. 2010;3:134–40.
16. Fernández-Frackelton M, Peterson M, Lewis RJ, et al. A bedside ultrasound curriculum for medical students: prospective evaluation of skill acquisition. Teach Learn Med. 2007;19:14–19.
17. Decara JM, Kirkpatrick JN, Spencer KT, et al. Use of hand-carried ultrasound devices to augment the accuracy of medical student bedside cardiac diagnoses. J Am Soc Echocardiogr. 2005;18:257–63.
18. Barloon TJ, Brown BP, Abu-Yousef MM, et al. Teaching physical examination of the adult liver with use of real-time sonography. Acad Radiol. 1998;5:101–3.
19. Butter J, Grant TH, Egan M, et al. Does ultrasound training boost Year 1 medical student competence and confidence when learning abdominal examination? Med Educ. 2007;41:843–8.
20. Arger PH, Schultz SM, Sehgal CM, et al. Teaching medical students diagnostic sonography. J Ultrasound Med. 2005;24:1365–9.

