

## Treating pseudomyxoma peritonei without heated intraperitoneal chemotherapy—a first look in New Zealand

Benjamin R Wheeler, Sumeet K Reddy, Diane Kenwright, John P Keating

### Abstract

**Background** Pseudomyxoma peritonei is a condition characterised by dissemination of mucin-producing neoplastic cells throughout the peritoneal cavity. There are two pathological subsets, disseminated peritoneal adenomucinosis and peritoneal mucinosis carcinomatosis. Once a lethal disease, cytoreductive surgery combined with heated intraperitoneal chemotherapy (HIPEC) is challenging debulking as the standard of care.

**Objective** We present the first case series detailing the postoperative morbidity, mortality and survival outcomes of patients treated for pseudomyxoma peritonei by cytoreductive surgery without heated intraperitoneal chemotherapy by a single surgeon.

**Design** Wellington Hospital clinical databases were retrospectively searched. Inclusion criteria were a diagnosis of pseudomyxoma peritonei with a major cytoreductive operation with the intention of complete cytoreductive clearance. Exclusion criteria were palliative debulking operations and patient records not available for analysis.

**Results** 25 patients underwent cytoreductive surgery between June 1999 and July 2011. Mean follow-up was 43.5 months (1.5–138). Histological classification was DPAM for 13/25 and PMCA for 12/25. Complete cytoreduction (CC-0 and CC-1) was achieved in 21/25 patients. There was no 30 day mortality following primary cytoreduction. Six patients underwent subsequent debulking/cytoreductive surgery; one patient died following repeat surgery. Clavien-Dindo grade 3 or 4 complications occurred in 7/25 patients. Combined 5-year survival was 64%, 92% for DPAM and 33% for PMCA.

**Conclusion** Cytoreductive surgery alone may result in comparable survival outcomes to those achieved with combined surgery and HIPEC in selected patients, especially for patients with DPAM.

Pseudomyxoma peritonei is a condition characterised by dissemination of mucin-producing neoplastic cells throughout the peritoneal cavity.<sup>1</sup> The originating tumour is usually a mucinous appendiceal neoplasm. Ovarian, urachal, pancreatic and colonic tumours have also been implicated.<sup>2–4</sup> There are several pathological grading systems in use. The classification proposed by Ronnett et al is used at our institution.

Two distinct subtypes are recognised, the more benign disseminated peritoneal adenomucinosis (DPAM), and peritoneal mucinous carcinomatosis (PMCA), the latter of which follows a more aggressive course. An intermediate grade tumour has also been described with a prognosis that falls between DPAM and PMCA.<sup>1</sup> More recently

similar two and three category systems have been proposed by Bradley et al<sup>5</sup> and Misdraji et al.<sup>6</sup>

Pseudomyxoma peritonei is a rare condition, with an incidence of 1–2 cases per million population, and this rate may be increasing.<sup>7</sup> The published literature over the last thirty years has been developed significantly, largely due to the efforts of Paul H Sugarbaker at the Washington Cancer Centre who established the first national centre of interest. The treatment that he has developed is for complete cytoreduction of all macroscopic disease within the peritoneal cavity, combined with heated intraperitoneal chemotherapy, usually with mitomycin C, prior to reconstruction of the gastrointestinal tract.<sup>8</sup>

In spite of an increasing uptake internationally of this technique to treat pseudomyxoma peritonei, there is a paucity of evidence guiding and evaluating the individual components of this multimodal therapy for this indication. Most published accounts are case series. There are no randomised controlled trials of HIPEC for pseudomyxoma peritonei.<sup>9,10</sup>

In New Zealand, the majority of cytoreductive surgery for this condition has been carried out at Wellington Hospital by a single surgeon. Following the adoption of the Sugarbaker procedure for a local patient in 1999, further patients from around the country have been referred for treatment.

A national consensus meeting involving medical and gynaecological oncologists was held and it was decided that there was insufficient evidence to support use of the heated intraperitoneal chemotherapy for this indication.

This case series reports the outcomes for the first 12 years of experience performing cytoreductive surgery with conventional chemotherapy alone for pseudomyxoma peritonei.

## Materials and Methods

A retrospective analysis of all patients receiving cytoreductive surgery at Wellington Hospital was undertaken from 1997 to July 2011. All patients in New Zealand are registered with a unique code on the National Health Index. This database was used to identify patients' date of death (where applicable) and their local General Practitioner.

Hospital databases were searched for operative and pathological coding and cross-referenced. Local electronic records were then searched to establish accurate coding. Paper records from Wellington Hospital and the referring hospital were then examined. The inclusion criteria were undergoing a Sugarbaker procedure for pseudomyxoma peritonei with curative intent, paper records being available for analysis and a minimum of 30 days of follow-up post-procedure.

Preoperative data including patient demographics, details of prior abdominal surgery, preoperative histology, and tumour markers (CEA, CA19-9 and CA125) were recorded. The theatre records, operation notes and histology were examined to determine length of operation, number and type of peritonectomies and visceral resections, and stoma requirement.

The Completeness of Cytoreduction Score (CCRS) was derived from the surgeon's operative records.<sup>11</sup> Postoperative ICU and hospital stay, morbidity and mortality, use of pre- and post-surgical chemotherapy, recurrence of disease, survival and follow-up were recorded and analysed.

The cytoreductive procedure is undertaken via a long midline incision from xiphisternum to the symphysis pubis, and involves stripping of peritoneum from up to six regions of the abdomen combined with visceral resections of involved organs as per the Sugarbaker procedure. Omentectomy, splenectomy, cholecystectomy and right hemicolectomy are commonly performed.<sup>8</sup> An ultrasonic surgical aspirator is used to facilitate the dissection, as previously described.<sup>12</sup>

At the end of the operative procedure the peritoneal cavity was washed out with warmed 50% Betadine solution for 10 minutes in view of its known tumouricidal properties.<sup>13</sup> This was followed by a saline lavage to remove all residual povidine-iodine solution. Prophylactic chest drains were placed if the diaphragmatic peritoneum was stripped. Intraperitoneal drains are placed according to the extent of dissection. All patients went to ICU postoperatively. Prophylactic TPN was initiated unless the dissection was limited.

Clinical follow-up for patients remaining under the care of Wellington Hospital consisted of three monthly clinic review and abdominopelvic CT scan at one year after surgery with further surveillance tailored to the patient's individual situation. Patients from outside the Wellington region underwent postoperative care as determined by their local referring surgeon.

Follow-up length was determined from the time of the first procedure to the last clinical interaction recorded at the base hospital or with the General Practitioner. For deceased patients the cause of death, if not apparent from hospital records, was confirmed from the General Practitioner records.

Patients having a CCRS score of 3 with residual nodules exceeding 2.5 cm were considered as immediate relapses. Recurrence was defined by radiological evidence of recurrent disease, recurrent disease on a subsequent laparotomy or on clinical grounds, where further CT or operative intervention was inappropriate.

Data was extracted from the database using SPSS-17 software. Kaplan-Meier survival analysis was used to determine 5-year overall survival. The survival curves were compared using the log-rank test. T test was used to compare the demographics of the palliative and curative groups. Prospective ethical approval was granted by the New Zealand Multi-Region Ethics Committee.

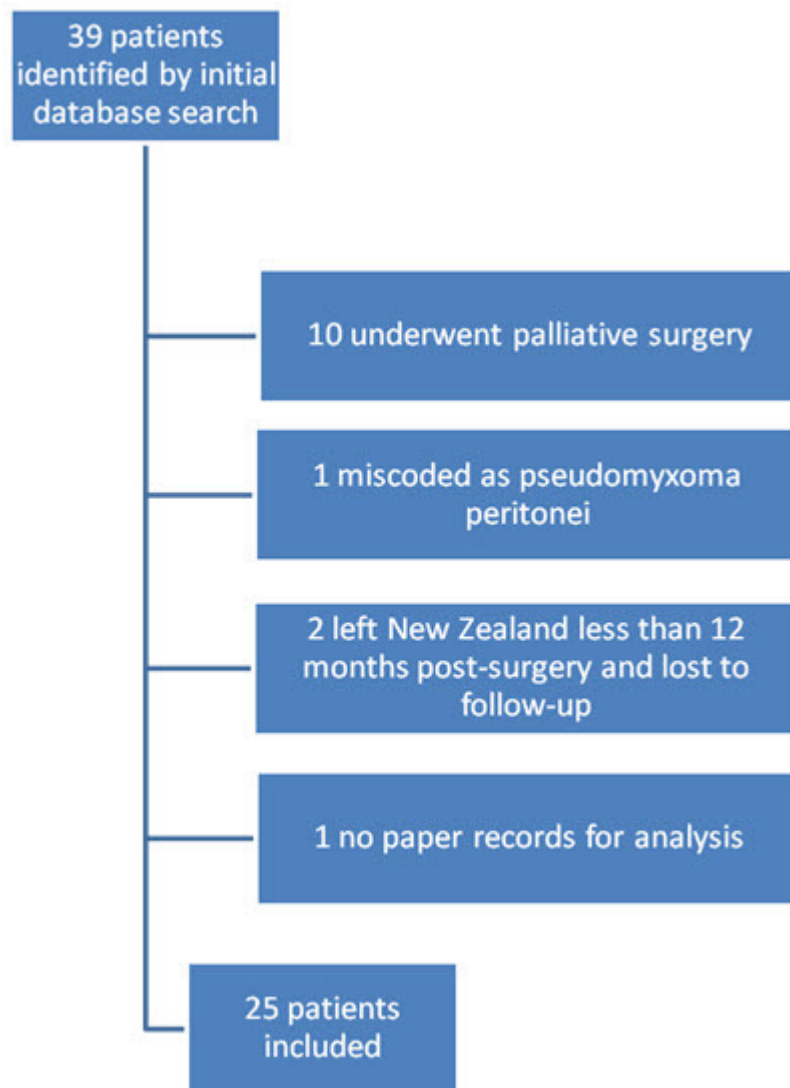
## Results

Thirty-nine patients were identified from database searching (see Figure 1); 14 patients were not included while 10 patients were deemed on clinical grounds to not be fit for a Sugarbaker procedure and underwent palliative debulking.

The mean age for the patients undergoing cytoreduction compared to the patients who underwent palliative debulking was 51.1 versus 61.8 years ( $P<0.01$ ). The mean American Society of Anaesthesiologists (ASA) Score for the patients undergoing cytoreduction compared to the patients who underwent palliative debulking was 2.1 versus 2.6 ( $P=0.04$ ). One patient was miscoded. Two patients left New Zealand shortly after their operation and were lost to follow-up. One patient's referring hospital notes were not available for analysis and therefore excluded.

The age of the 25 patients who underwent cytoreductive surgery ranged from 32 to 66 years with a median age of 49 years; 16 of 25 patients were female. There was a wide range of methods of presentation. Eight patients had mucinous material within a ventral hernia. Five patients were diagnosed during laparoscopy or laparotomy for another indication. Eight patients presented with abdominal distension, pain or unexplained ascites. Three patients were identified from a workup for an ovarian mass. One patient was an incidental finding on abdominal radiology for another indication.

**Figure 1. Patients receiving cytoreductive surgery at Wellington Hospital from 1997 to July 2011**



Twenty-two of the 25 patients had undergone prior surgery for their pseudomyxoma peritonei prior to their referral to Wellington Hospital for definitive surgery. 12 had undergone an exploratory laparotomy with diagnostic biopsy only (Prior Surgical Score=1), 10 had undergone laparotomy with some visceral resections (Prior Surgical Score=2).<sup>14</sup> One patient underwent a second cytoreductive operation.

Of the 22 patients who had prior surgery, histology was available in 21. The preoperative histology was non-diagnostic in five cases, DPAM in nine and PMCA in seven. Following full histopathological analysis by an experienced pathologist, the preoperative histology was confirmed in 11 of 16 cases. Four of the preoperative DPAM cases were upgraded to PMCA, and one patient was downgraded from PMCA to DPAM.

In total, 13 patients were classified as DPAM and 12 as PMCA. The primary tumour was identified as appendiceal in 21, ovarian in one patient and unknown in three cases.

Characteristics of patients' surgery, chemotherapy and in-hospital stay are detailed in Table 1. The extent and type of visceral and peritoneal resections are listed in Table 2. CCRS-0 or 1 was achieved in 21 of 25 patients. There were 17 Clavien-Dindo grade 3 or 4 complications, occurring in 7 of 25 patients, as shown in Table 3. There were no deaths within 30 days of primary cytoreduction.

**Table 1. Patient characteristics**

Variables	DPAM (N=13)	PMCA (N=12)	Overall (N=25)
<b>Demographics</b>			
Mean age (range)	48 (32–65)	53 (42–66)	50 (32–66)
Male/Female	3/10	6/6	9/16
Mean body mass index (range)	27.5 (20.4–40.4)	28.9 (20.9–45.5)	28.2 (20.4–45.5)
<b>Treatment details</b>			
Number receiving preop. chemotherapy	1	3	4
Median operating time (range)	6hr 59min (3hr 46min–12hr 38min)	8hr 23min (5hr 10min–12hr 22min)	8hr 0min (3hr 46min–12hr 38min)
Intraoperative units of packed red cells transfused (range)	4 (0–16)	7 (0–32)	5 (0–32)
Intraoperative units of fresh frozen plasma transfused (range)	2 (0–8)	4 (0–26)	3 (0–26)
Median days in ICU (range)	2 (0–4)	1.5 (0–34)	2 (0–34)
Median days on TPN (range)	8 (0–23)	7 (0–72)	7 (0–72)
Median hospital stay in days (range)	11 (5–45)	20 (10–92)	16 (5–92)
Postoperative chemotherapy	3	7	10

**Table 2. Operative characteristics**

Visceral resections and number of patients		Peritonectomies and number of patients	
Rectosigmoid	6	Anterior parietal	22
Right colectomy	12	Omentectomy ± splenectomy	22
Total abdominal colectomy	5	Right and left subphrenic	19
Small bowel resection	2	Lesser omentectomy + omental bursa stripping ± cholecystectomy	18
Gastrectomy	3	Pelvic	22
Mean number of resections	1.3	Mean number of peritonectomies	4.1

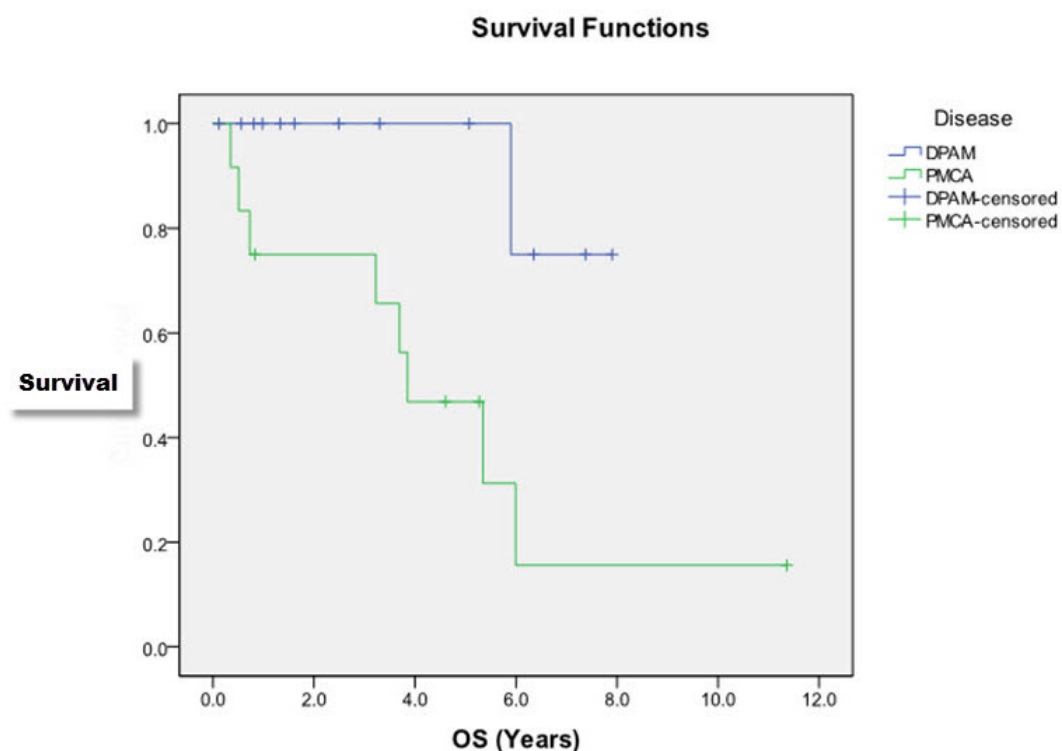
**Table 3. Clavien-Dindo postoperative complications**

Patient	Grade 3	Grade 4	Grade 3/4 combined
1	Postoperative haemorrhage	N/A	1
2	Ascites, pulmonary embolism	Postoperative haemorrhage	3
3	Central venous line sepsis	N/A	1
4	Respiratory distress, pleural effusion, UTI	Bile leak, hypotension	5
5	Enterocutaneous fistula, pleural effusion	Respiratory distress, pulmonary embolism, wound infection	5
6	N/A	Pneumonia	1
7	N/A	Postoperative haemorrhage	1
Total	9	8	17

Five patients underwent subsequent debulking procedures. Four of these were performed by the local surgeon caring for the patient. Two were performed by the cytoreductive surgeon. One of these procedures was an attempted salvage cytoreduction. This patient died subsequent to this operation. The patient presented acutely on postoperative day 19 under another surgeon's care, emergency gastroscopy was performed and multiple gastric ulcers were seen oozing gelatinous fluid. The patient was taken to the operating theatre, where the gastric disease was deemed to be unresectable by the operating surgeon.

The 5-year overall survival was 64%. For the 13 patients with DPAM, the 5-year survival was 92%. The mean survival for patients with DPAM was 7.4 years. For the 12 patients with PMCA, the 5-year survival was 33%. The Kaplan-Meier survival curves are demonstrated in Figure 2. The mean survival for this group was 4.7 years. This difference in survival was compared using the log-rank test and was statistically significant with a P value of 0.01. Mean follow-up was 43.5 months (range 1.5–138 months).

**Figure 2. The Kaplan-Meier survival curves**



## Discussion

Pseudomyxoma peritonei is uniquely suited as a model of peritoneal surface malignancy due to its indolent nature and lack of metastatic potential. Due to its rarity, the evidence base for treatment relies to date on the accumulation of case

series.<sup>15</sup> There have been no randomised controlled trials of the standard treatment regime and it has been suggested that these trials may never occur.<sup>16</sup>

In this study we have demonstrated that acceptable outcomes can be achieved without the use of HIPEC, particularly with the more pathologically benign DPAM. Reported figures from published case series vary widely dependent on many variables, including patient demographics, tumour characteristics and surgeon experience.

Exclusion criteria are rarely listed and poorly defined. Patients declined for definitive treatment are often not discussed in detail if at all. This renders decision-making regarding treatment suitability fraught with difficulty.<sup>11,17–22</sup> At our institution we have made individual decisions on a case by case basis with a resultant lower mean age and ASA for the included patients.

A review of the literature shows a range of published outcomes. Overall survival ranges from 53–73%. DPAM patients consistently have better outcomes, with 5 year survivals of 70–90%. Morbidity is difficult to compare due to inconsistent definitions and reporting but range from 7–40%. 30 day mortality is 1.6–4.4%.<sup>11,17–22</sup>

The results from this series are consistent with these figures without the use of HIPEC. The use of chemotherapy was idiosyncratic as most patients were referred from outside the Wellington Hospital catchment area. These patients preoperative and post-discharge care was determined by their referring surgeon and the local Oncology Service.

There are limited comparisons of cytoreductive surgery with and without HIPEC in the published literature. In a case series of 60 patients by Hadi et al from St George's Hospital in New South Wales, Australia, a survival advantage was conferred from the use of HIPEC.<sup>23</sup> This series involved only 23 patients with pseudomyxoma peritonei. The non-HIPEC patients were from the beginning of the series prior to HIPEC becoming available. This result may be confounded by the learning curve involved in cytoreductive surgery.

Chua et al<sup>24</sup> have published the outcomes for the 2,298 patients registered in the recently established Peritoneal Surface Oncology Group International registry, of which some results have been previously reported. 11% of these patients did not receive intraperitoneal chemotherapy, the reasons for which are not elaborated upon. Univariate analysis showed these patients to have a poorer progression-free, but not overall survival. As stated by the authors, this suggests that cytoreduction is more important than intraperitoneal chemotherapy for achieving optimal outcomes.

The high survival rate that can be achieved for DPAM patients without the use of intraperitoneal chemotherapy would suggest that this treatment modality may be an unnecessary burden. We compared preoperative histology, where available, to the definitive histological diagnosis from post-cytoreductive specimens, but there was insufficient correlation to suggest that preoperative biopsy might be sufficient to separate out PMCA patients for consideration of a more aggressive strategy.

If it was accepted that patients with DPAM could be safely excluded from intraperitoneal chemotherapy, combination strategies involving preoperative histology and peritoneal cytology, radiological findings and frozen section analysis may provide



enough certainty to target the chemotherapeutic regimes towards the patients affected by the unfavourable PMCA.

The centralisation of treatment into specialised peritoneal surface malignancy units has allowed for enough experience in a rare condition and it's operation treatment for impressive results such as those achieved by Youssef *et al.*<sup>21</sup> This maximisation of surgical performance is an eminently suitable setting for the first randomised trials of pseudomyxoma peritoneal treatment to occur.

**Competing interests:** Nil.

**Author information:** Benjamin R Wheeler, General Surgical Registrar, Department of General Surgery; Diane Kenwright, Pathologist, Department of Pathology; John P Keating, Colorectal Surgeon, Department of General Surgery; Capital and Coast District Health Board, Wellington

**Correspondence:** Dr John P Keating, Wellington Hospital, Riddiford Street, Newtown, Wellington 6021, New Zealand. Email: Dr Benjamin R Wheeler, [BRLWheeler@gmail.com](mailto:BRLWheeler@gmail.com)

## References:

1. Ronnett BM, Yan H, Kurman RJ, et al. Patients with pseudomyxoma peritonei associated with disseminated peritoneal adenomucinosis have a significantly more favorable prognosis than patients with peritoneal mucinous carcinomatosis. *Cancer*. 2001;92(1):85-91.
2. Yan TD, Sugarbaker PH, Brun EA. Pseudomyxoma peritonei from mucinous adenocarcinoma of the urachus. *J Clin Oncol*. 2006 Oct 20;24(30):4944-6
3. Mitsuhashi T, Murata N, Sobajima J, et al. A case of pseudomyxoma peritonei with a pancreatic cancer treated by the intraperitoneal administration of cisplatin. [Article in Japanese] *Gan To Kagaku Ryoho*. 2001 Oct;28(11):1670-3.
4. Saluja M, Kenwright DN, Keating JP. Pseudomyxoma peritonei arising from a mucinous borderline ovarian tumour: Case report and literature review. *Aust N Z J Obstet Gynaecol*. 2010 Aug;50(4):399-403.
5. Bradley RF, Stewart JH IV, Russell GB, et al. Pseudomyxoma peritonei of appendiceal origin: a clinicopathologic analysis of 101 patients uniformly treated at a single institution, with literature review. *Am J Surg Pathol*. 2006;30(5):551-559.
6. Misdraji J. Appendiceal mucinous neoplasms: controversial issues. *Arch Pathol Lab Med*. 2010 Jun;134(6):864-70.
7. Smeenk RM, van Velthuysen ML, Verwaal VJ, Zoetmulder FA. Appendiceal neoplasms and pseudomyxoma peritonei: a population based study. *Eur J Surg Oncol*. 2008;34(2):196-201.
8. Sugarbaker PH. Peritonectomy procedures. *Annals of Surgery*. 1995;221(1):29-42.
9. Bryant J, Clegg AJ, Sidhu MK, et al. Systematic review of the Sugarbaker procedure for pseudomyxoma peritonei. *British Journal of Surgery*. 2005;92(2):153-8.
10. Yan TD, Black D, Savady R, Sugarbaker PH. A systematic review on the efficacy of cytoreductive surgery and perioperative intraperitoneal chemotherapy for pseudomyxoma peritonei. *Annals of Surgical Oncology*. 2006;14(2):484-92.
11. Sugarbaker PH, Chang D. Results of treatment of 385 patients with peritoneal surface spread of appendiceal malignancy. *Ann Surg Oncol*. 1999;6(8):727-31.
12. Keating JP, Frizelle FA. Use of a ultrasonic surgical aspiratory in operation cytoreduction of pseudomyxome peritonei. *Dis Colon Rectum*. 2000;43:559-560.
13. Umpleby HC, Williamson RCN. The efficacy of agents employed to prevent anastomotic recurrence in colorectal carcinoma. *Ann R Coll Surg Engl*. 1984 May;66(3):192-4



14. Sugarbaker PH. Cytoreductive surgery and peri-operative intraperitoneal chemotherapy as a curative approach to pseudomyxoma peritonei syndrome. *European Journal of Surgical Oncology*. 2001;27(3):239-43.
15. Yan TD, Black D, Savady R, Sugarbaker PH. A systematic review on the efficacy of cytoreductive surgery and perioperative intraperitoneal chemotherapy for pseudomyxoma peritonei. *Ann Surg Oncol*. 2007 Feb;14(2):484-92.
16. González-Moreno S. Pseudomyxoma peritonei: a rare disease and a disease model in peritoneal surface oncology. *Clin Trans Oncol*. 2011;13(4):211-212.
17. Miner TJ, Shia J, Jaques DP, et al. Long-term survival following treatment of pseudomyxoma peritonei. *Ann Surg*. 2005 Feb;241(2):300-8.
18. Stewart JH, Shen P, Russell GB, Levine EA. Appendiceal neoplasms with peritoneal dissemination: outcomes after cytoreductive surgery and intraperitoneal hyperthermic chemotherapy. *Ann Surg Oncol*. 2006 May;13(5):624-34.
19. Smeenk RM, Verwaal VJ, Antonini N, Zoetmulder F. Survival analysis of pseudomyxoma peritonei patients treated by cytoreductive surgery and hyperthermic intraperitoneal chemotherapy. *Ann Surg*. 2007 Jan;245(1):104-9.
20. Elias D, Honoré C, Ciuchendéa R, et al. Peritoneal pseudomyxoma: results of a systematic policy of complete cytoreductive surgery and hyperthermic intraperitoneal chemotherapy. *Br J Surg*. 2008 Sep;95(9):1164-71.
21. Youssef H, Newman C, Chandrakumaran K, et al. Operative findings, early complications, and long-term survival in 456 patients with pseudomyxoma peritonei syndrome of appendiceal origin. *Dis Colon Rectum*. 2011 Mar;54(3):293-9.
22. Elias D, Gilly F, Quenet F, et al. Pseudomyxoma peritonei: French multicentric study of 301 patients treated with cytoreductive surgery and intraperitoneal chemotherapy. *Eur J Surg Oncol*. 2010 May;36(5):456-62. Epub 2010 Mar 12.
23. Hadi R, Saunders V, Utkina O, et al. Review of patients with peritoneal malignancy treated with peritonectomy and heated intraperitoneal chemotherapy. *ANZ J Surg*. 2006;76(3):156-61.
24. Chua TC, Moran BJ, Sugarbaker PH, et al. Early- and long-term outcome data of patients with pseudomyxoma peritonei from appendiceal origin treated by a strategy of cytoreductive surgery and hyperthermic chemotherapy. *J Clin Oncol*. 2012;30(20):2449-56.